



# GRAND ROUNDS (February 14, 2020)

Sarmiento/Velasco/Tirol/Casipe



DEPARTMENT OF OTORHINOLARYNGOLOGY  
PHILIPPINE GENERAL HOSPITAL

# VISION

The Department of Otorhinolaryngology shall be an internationally recognized center of excellence in the field of Otorhinolaryngology and Head and Neck Surgery

# MISSION

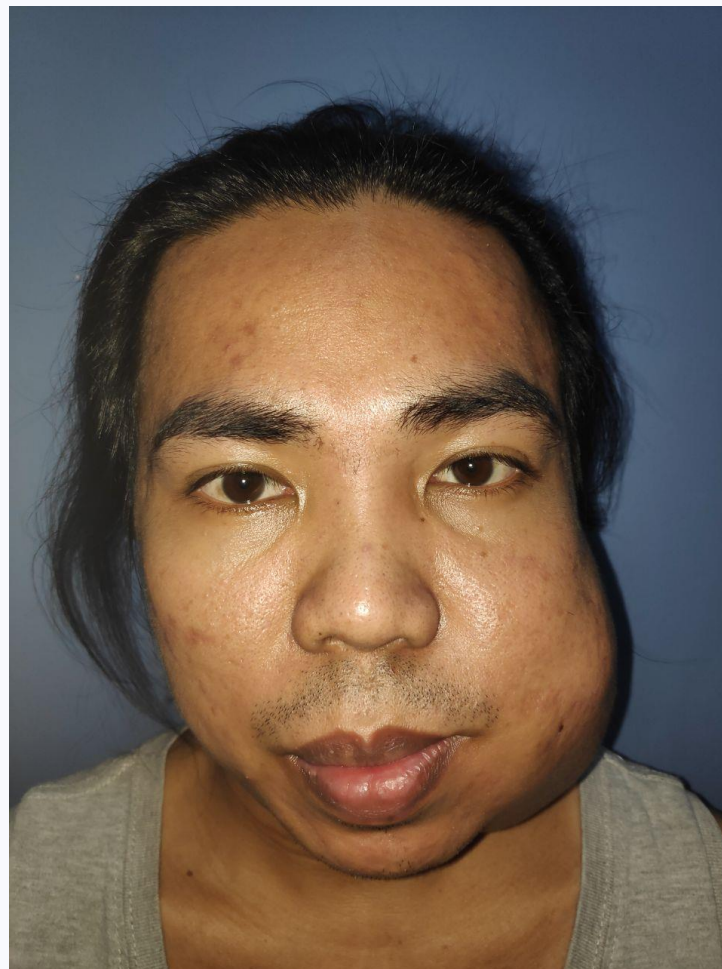
The health needs of the Filipino shall be its prime consideration.

It shall provide excellence and leadership in the different aspects in Otolaryngology – Head and Neck Surgery by teaching, providing exemplary clinical practice and dynamically pursuing relevant researches beneficial to the community in an environment guided by moral, ethical and spiritual values.



# General Information

- PP
- 32/M
- Single
- Roman Catholic
- Rosario, Northern Samar



\*with signed consent

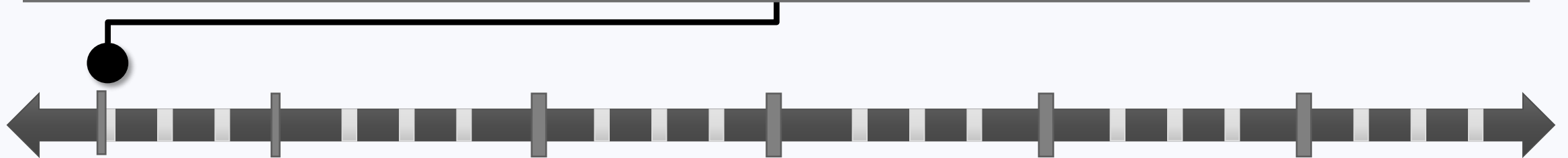
# Chief Complaint

**Left mandibular mass**

# History of Present Illness

## 12 years PTC (2008)

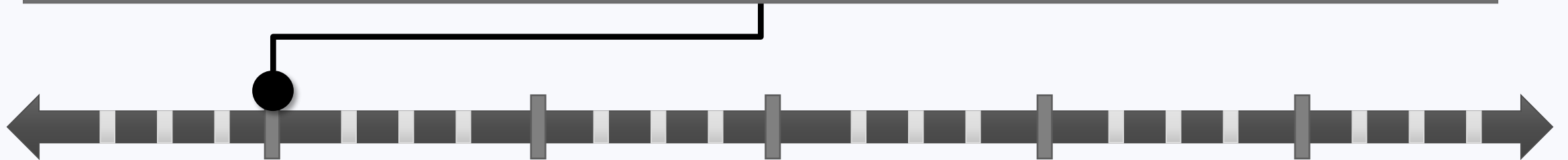
Patient noted onset of swollen gums in the left mandibular area with associated bleeding, tenderness, and loose dentition. He sought consult with a dentist and advised panoramic x-ray. The imaging revealed impacted 3<sup>rd</sup> molar. Extraction of the impacted 3<sup>rd</sup> molar was done with no relief of swelling.



# History of Present Illness

## 10 years PTC (2010)

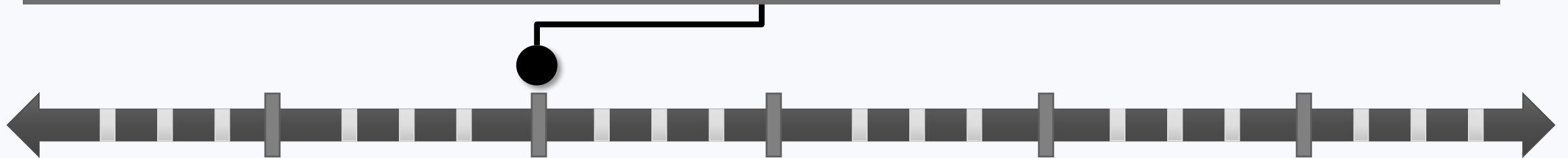
Patient noted occurrence of intraoral mass on the left lower molar area which was tender and bled on manipulation, manifesting extraorally as a bulge at the mandibular area. He tolerated the symptoms hence no consult done.



# History of Present Illness

## 4 years PTC (2016)

Patient noted gradual enlargement of the left alveolar mass now extending to the submandibular area. He consulted with a dentist. Panoramic x-ray was done which showed osteomyelitis. He was given clindamycin which he allegedly took for 3 months.

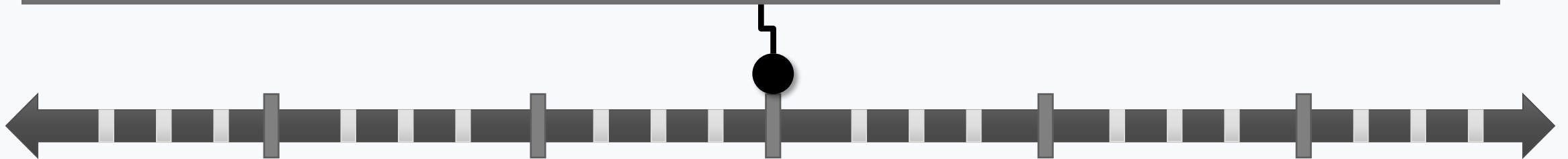




# History of Present Illness

## 2 years PTC (2018)

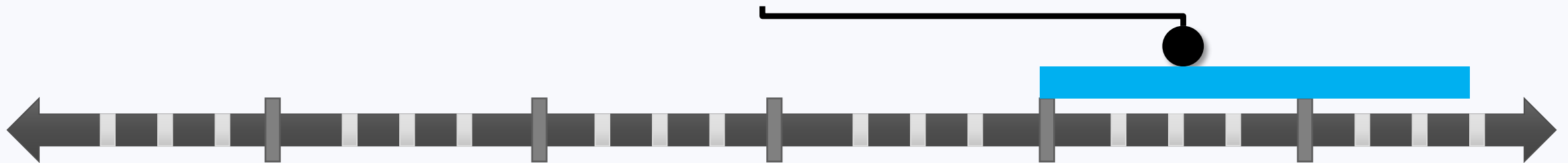
He went to PGH due to persistence of symptoms and progression in the size of the left mandibular mass. Incision biopsy and Panoramic Xray were done revealed Ameloblastoma. He was then advised surgery.



# History of Present Illness

## In the interim

There was gradual enlargement of the mass but no associated trismus, bleeding, discharge or skin changes.



# Past Medical History

- (-) hypertension
- (-) diabetes mellitus
- (-) previous hospitalization
- (-) allergy to food and medications
- (-) heart/lung/kidney/liver disease

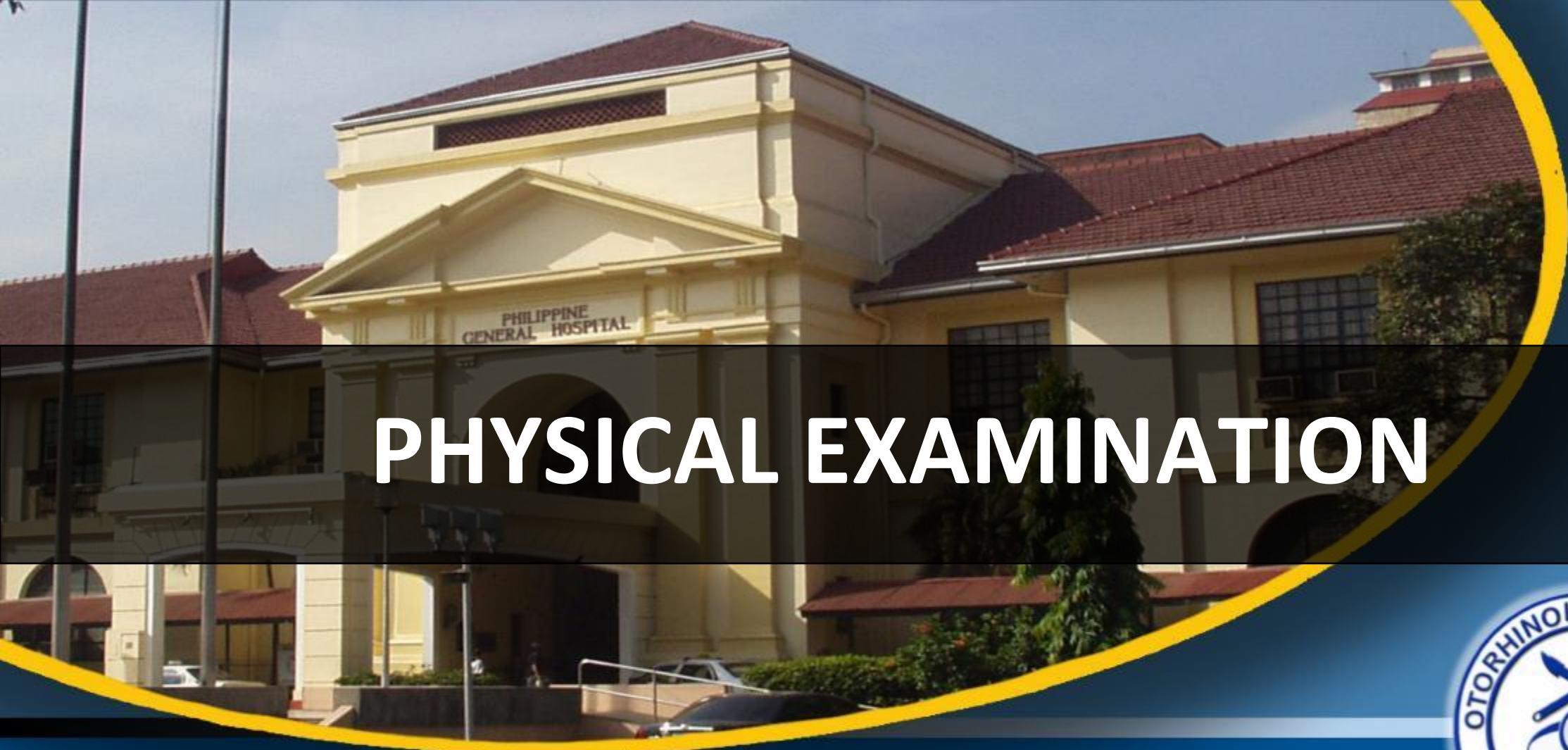
# Family Medical History

- (+) hypertension on both maternal and paternal side
- (-) diabetes mellitus
- (-) bronchial asthma
- (-) pulmonary tuberculosis
- (-) similar illness in the family



# Personal and Social History

- Nonsmoker
- Occasional alcoholic beverage drinker
- Denies illicit drug use
- Works as a barber and freelance make-up artist
- 1 sexual partner of unknown promiscuity



# PHYSICAL EXAMINATION



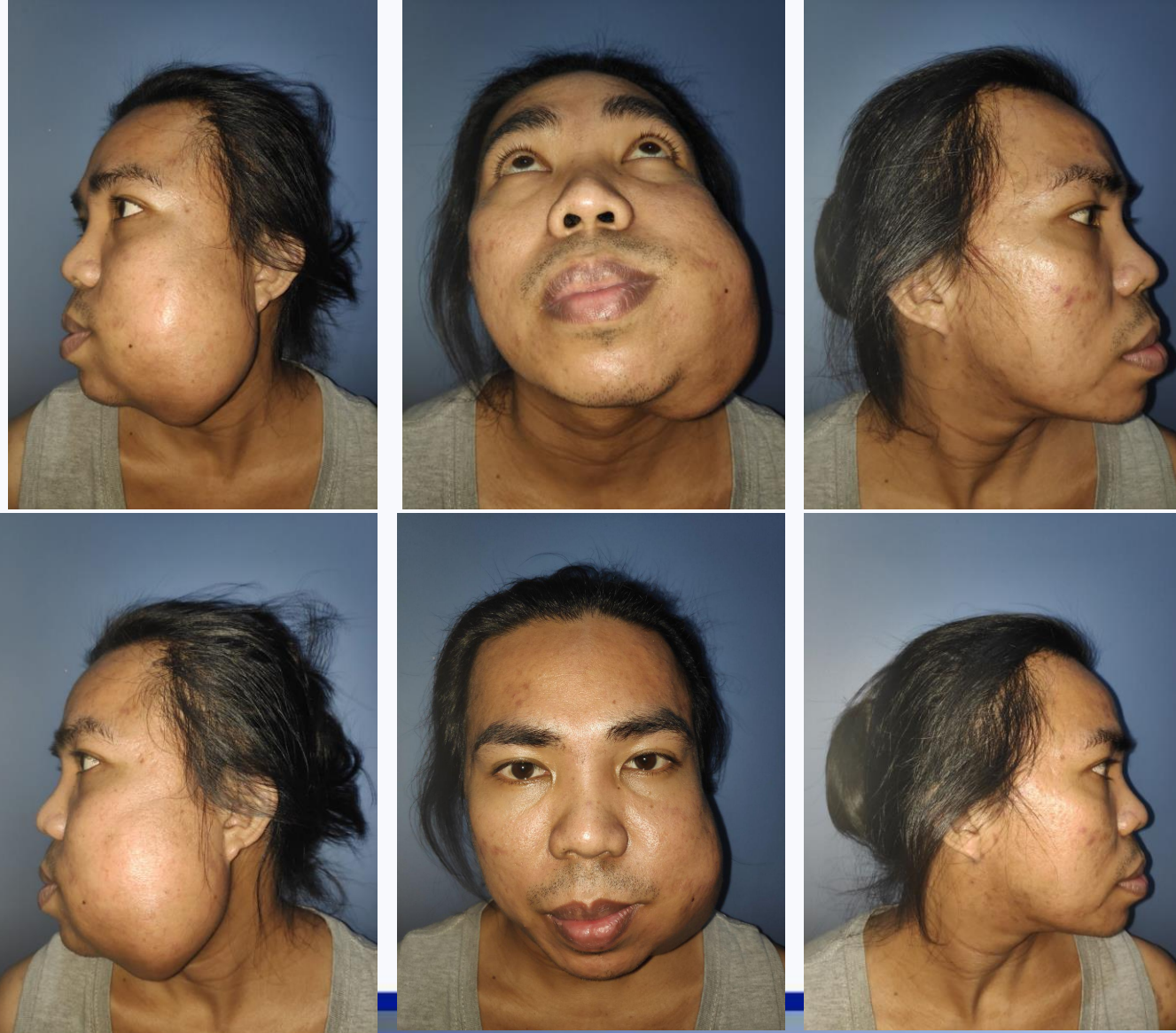DEPARTMENT OF OTORHINOLARYNGOLOGY  
PHILIPPINE GENERAL HOSPITAL

# SYSTEMIC PHYSICAL EXAM

<b>General</b>	Awake, alert, cooperative, not in cardiorespiratory distress
<b>Vital signs</b>	BP 120/80, HR 82, T 36.5, RR 20, O2 98% Height: 163 cm Weight: 62 kg
<b>Lungs</b>	Equal chest expansion, clear breath sounds
<b>Chest</b>	Adynamic precordium
<b>GI</b>	Soft flat abdomen, normoactive bowel sounds, no masses and no tenderness upon palpation
<b>Extremities</b>	Full equal pulses, pink nail beds, capillary refill time less than 2 seconds
<b>Neurologic</b>	(-) cranial nerve, motor, and sensory deficits, normal reflexes



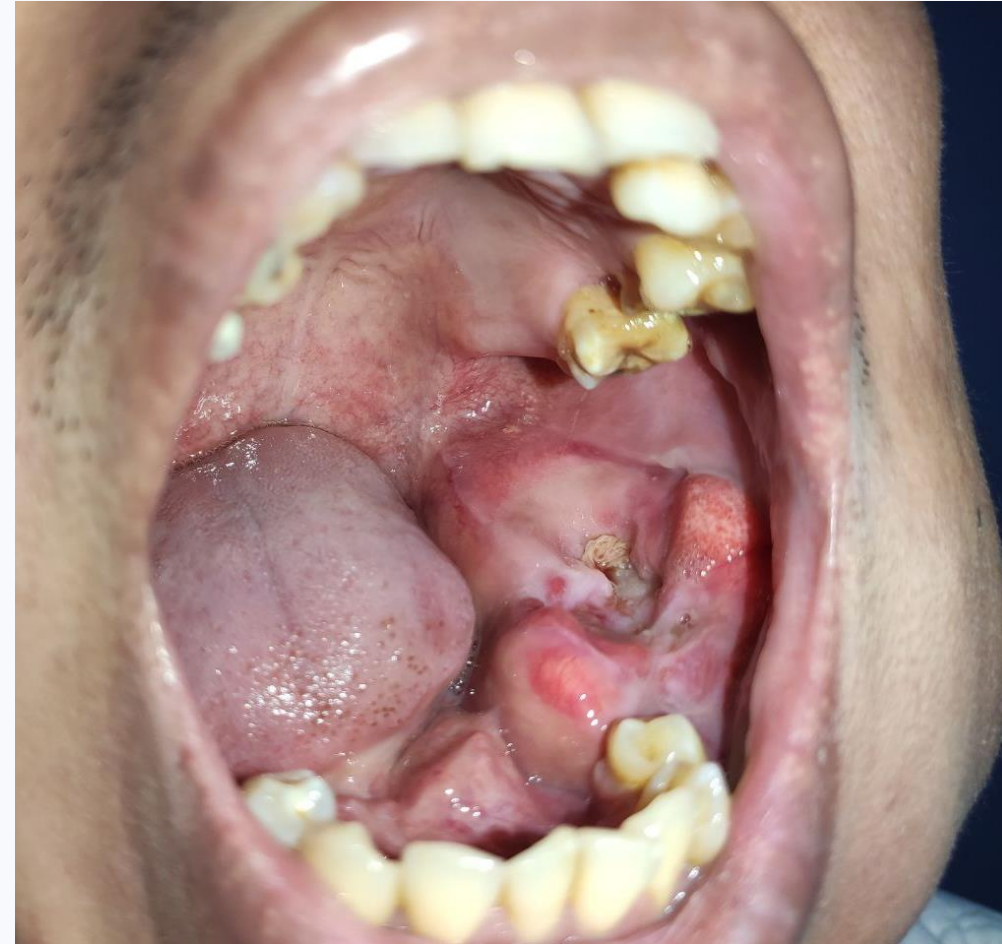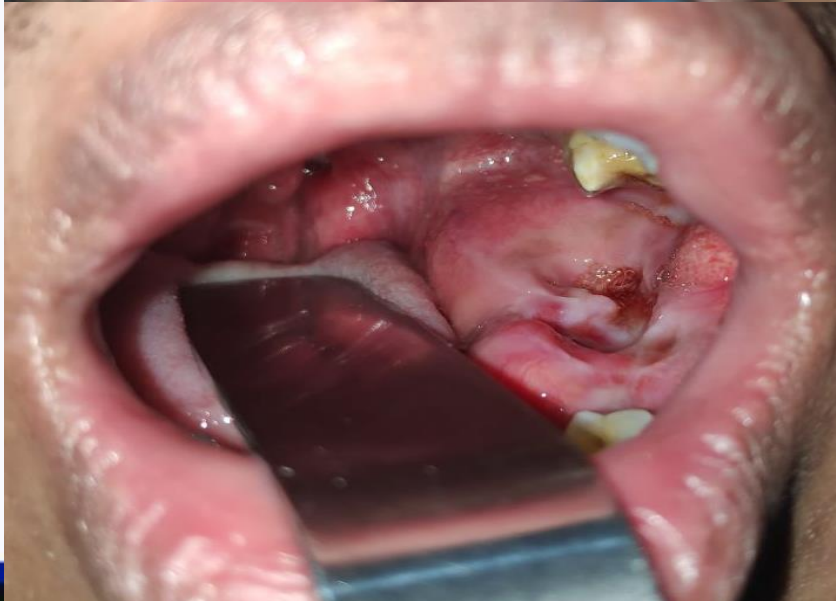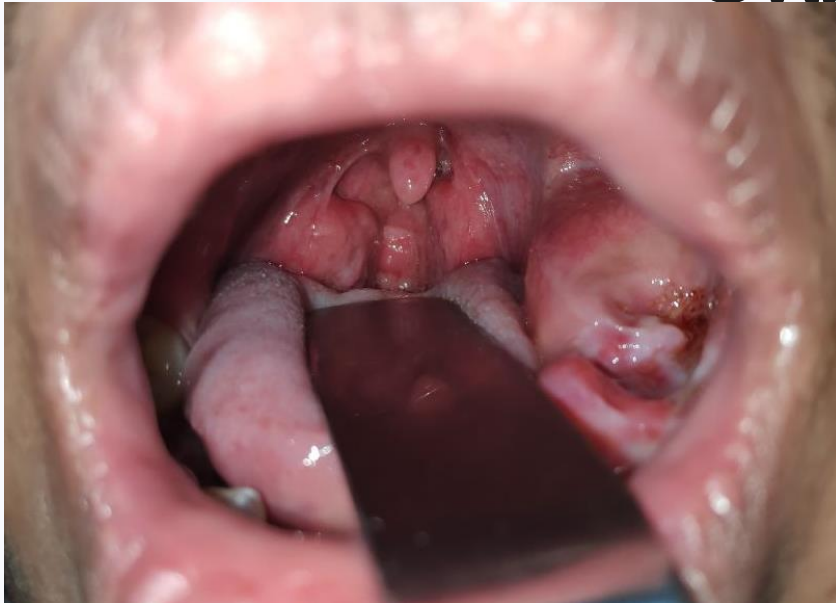# HEAD & NECK EXAMINATION



\*with signed consent

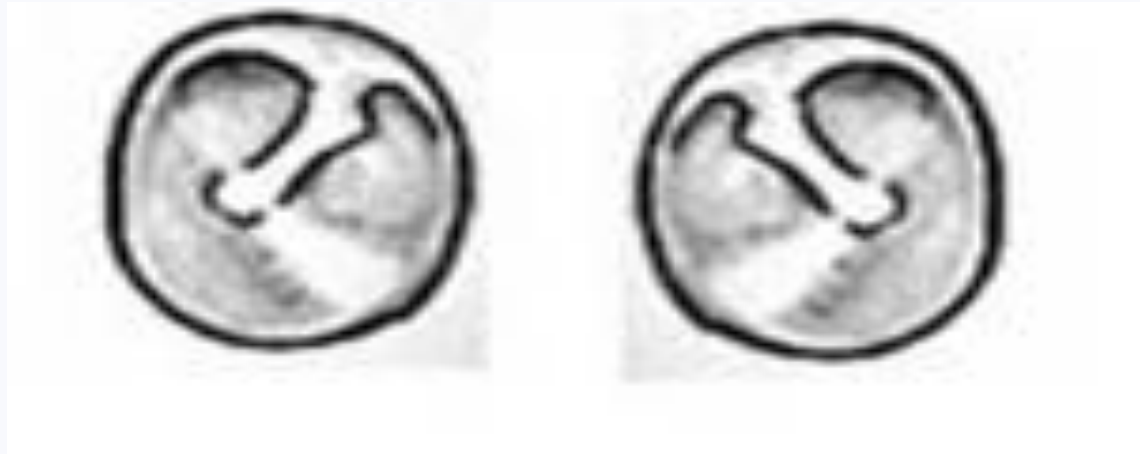


# ORAL CAVITY EXAM



\*with signed consent

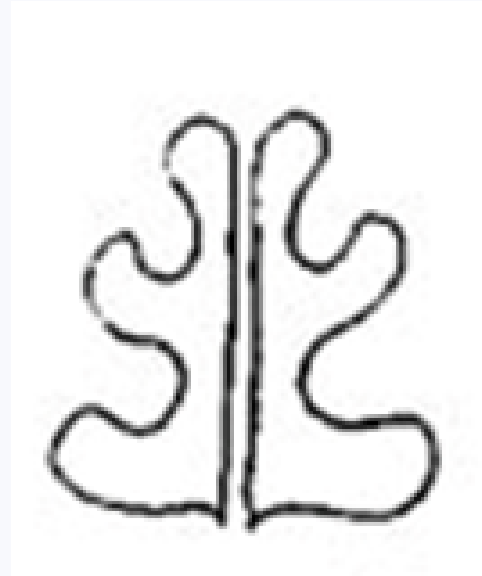# OTOLOGIC EXAM



Intact tympanic membrane, AU  
(+) cone of light, AU  
No discharge or bleeding  
No masses or lesions noted

# NASAL EXAM

Superior

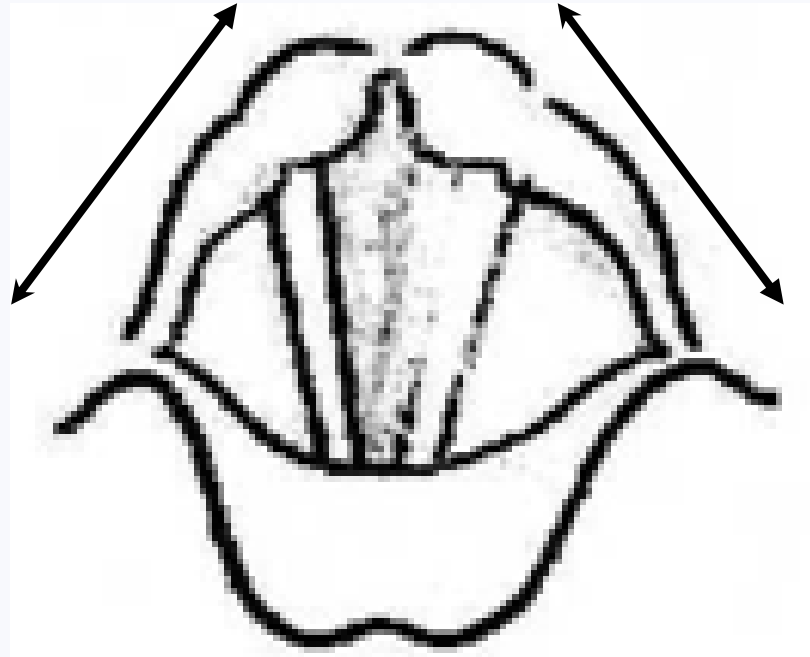


Septum midline

No masses or lesions

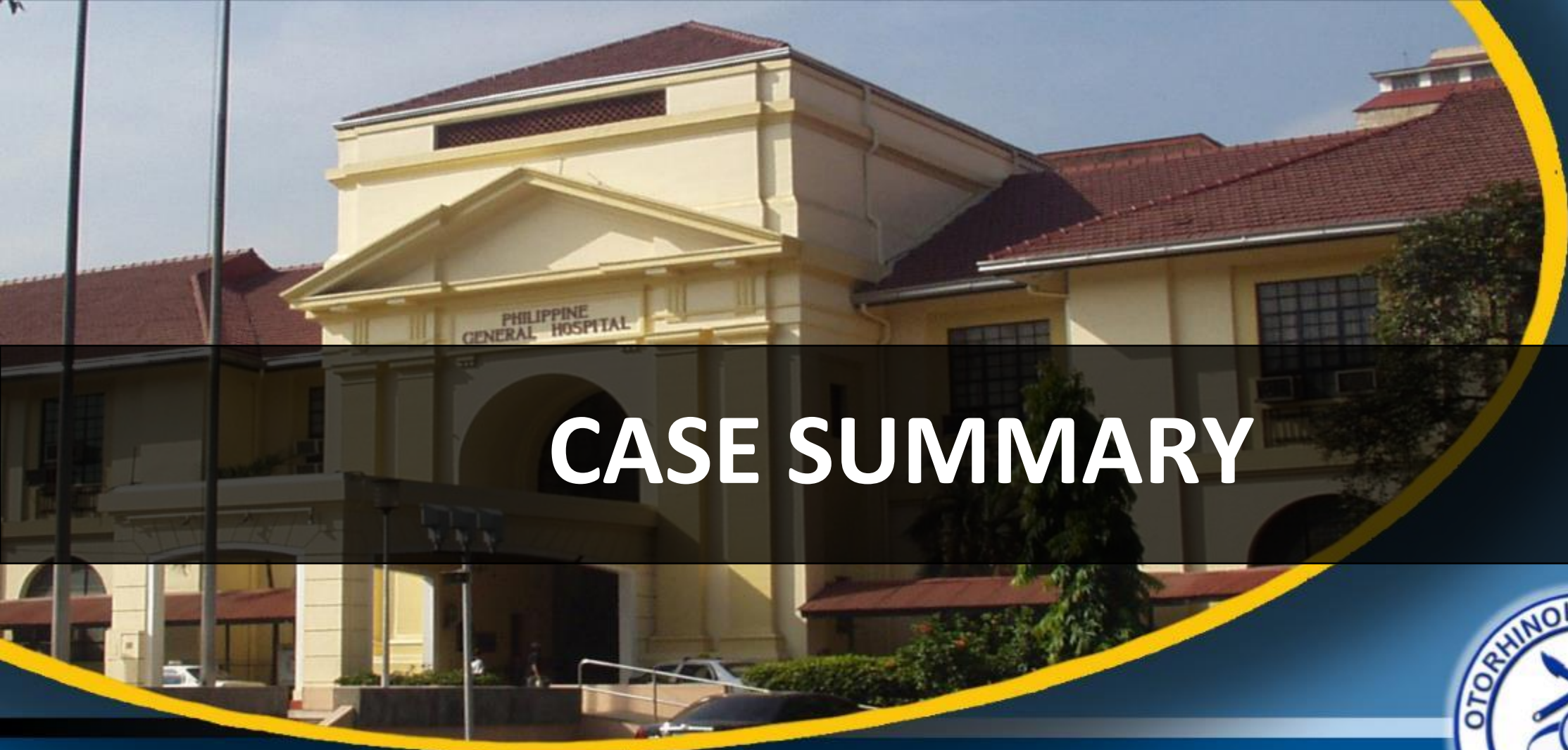No discharge or bleeding

# LARYNGOSCOPY



- Fully mobile vocal cords
- No masses noted





PHILIPPINE  
GENERAL HOSPITAL

# CASE SUMMARY



DEPARTMENT OF OTORHINOLARYNGOLOGY  
PHILIPPINE GENERAL HOSPITAL

# Diagnositics

- Cone Beam CT of the Mandible
  - 6.7x4.0x4.9 cm fairly to well-circumscribed, expansile, hypodense lesion from the angle of the left mandible, with soap bubble appearance, extending to the ramus
- CT Angiography of both lower extremities
  - Patent peroneal arteries, no aneurysm, stenosis, or AV malformation

- 32/M from Samar
- 10 year history of a gradually enlarging left mandibular mass with no note of trismus or dysphagia
- 12x10x6 cm firm, fixed, nontender, non-erythematous left mandibular mass, no ulceration, no skin break





PHILIPPINE  
GENERAL HOSPITAL

# DISCUSSION



DEPARTMENT OF OTORHINOLARYNGOLOGY  
PHILIPPINE GENERAL HOSPITAL



# Ameloblastoma

- Neoplasm of the enamel organ
- Usually arises from the lining of the odontogenic cyst, reduced enamel epithelium, or odontogenic rests
- Most aggressive of the benign odontogenic tumor

*6<sup>th</sup> Edition Cummings Otolaryngology*

# Ameloblastoma

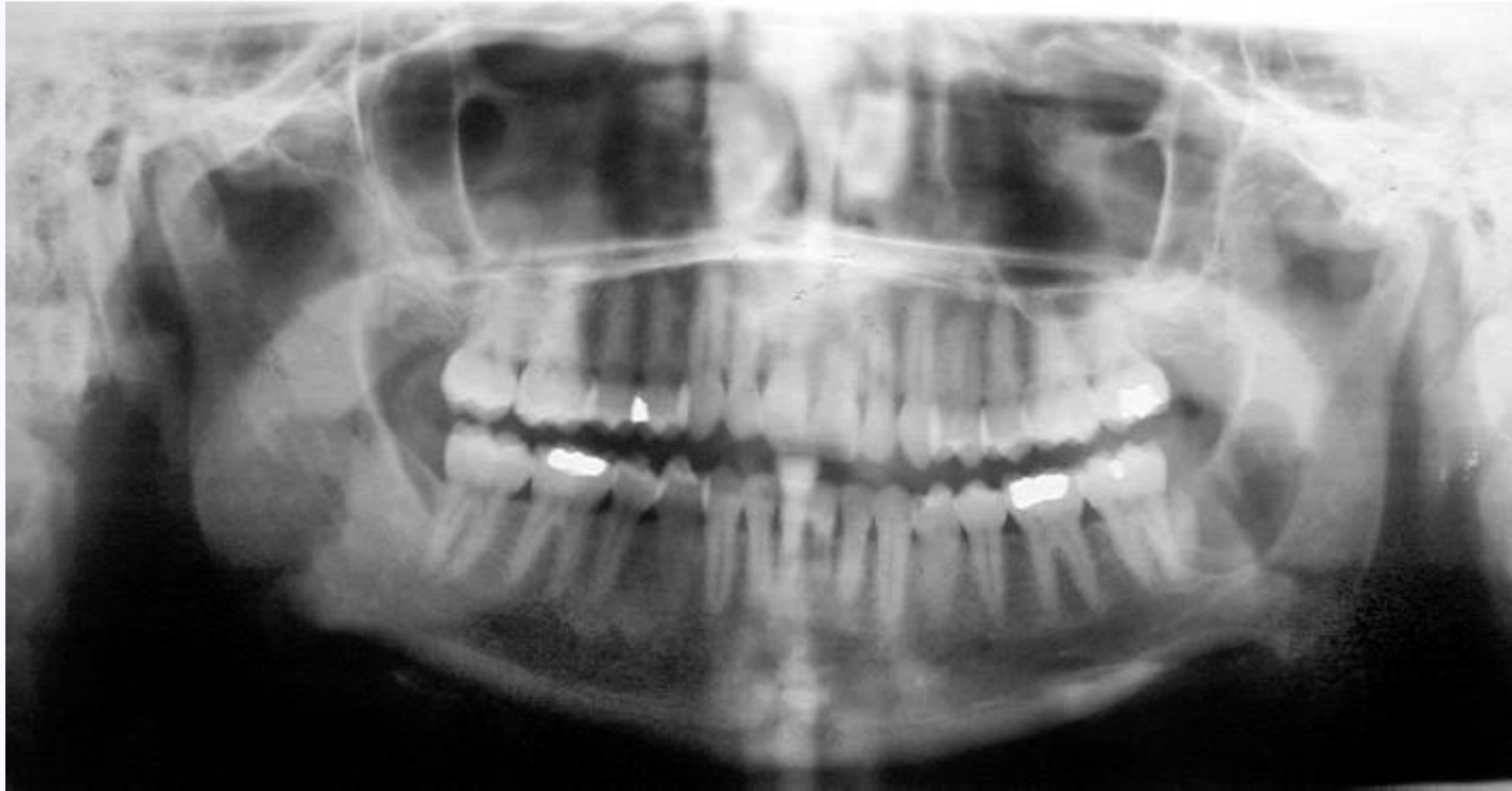- Can occur in maxilla and mandible
- Around 80% occur in the mandible
- Important prognostic factor is the location

*6<sup>th</sup> Edition Cummings Otolaryngology*

# Radiographic findings

- May appear as well-demarcated unilocular radiolucencies
- Indistinguishable from other cysts or from benign tumors of the jaws
- Larger lesions may become more easy to recognize radiographically
- “soap bubble” or honeycomb appearance.

*6<sup>th</sup> Edition Cummings Otolaryngology*



DEPARTMENT OF OTORHINOLARYNGOLOGY  
PHILIPPINE GENERAL HOSPITAL

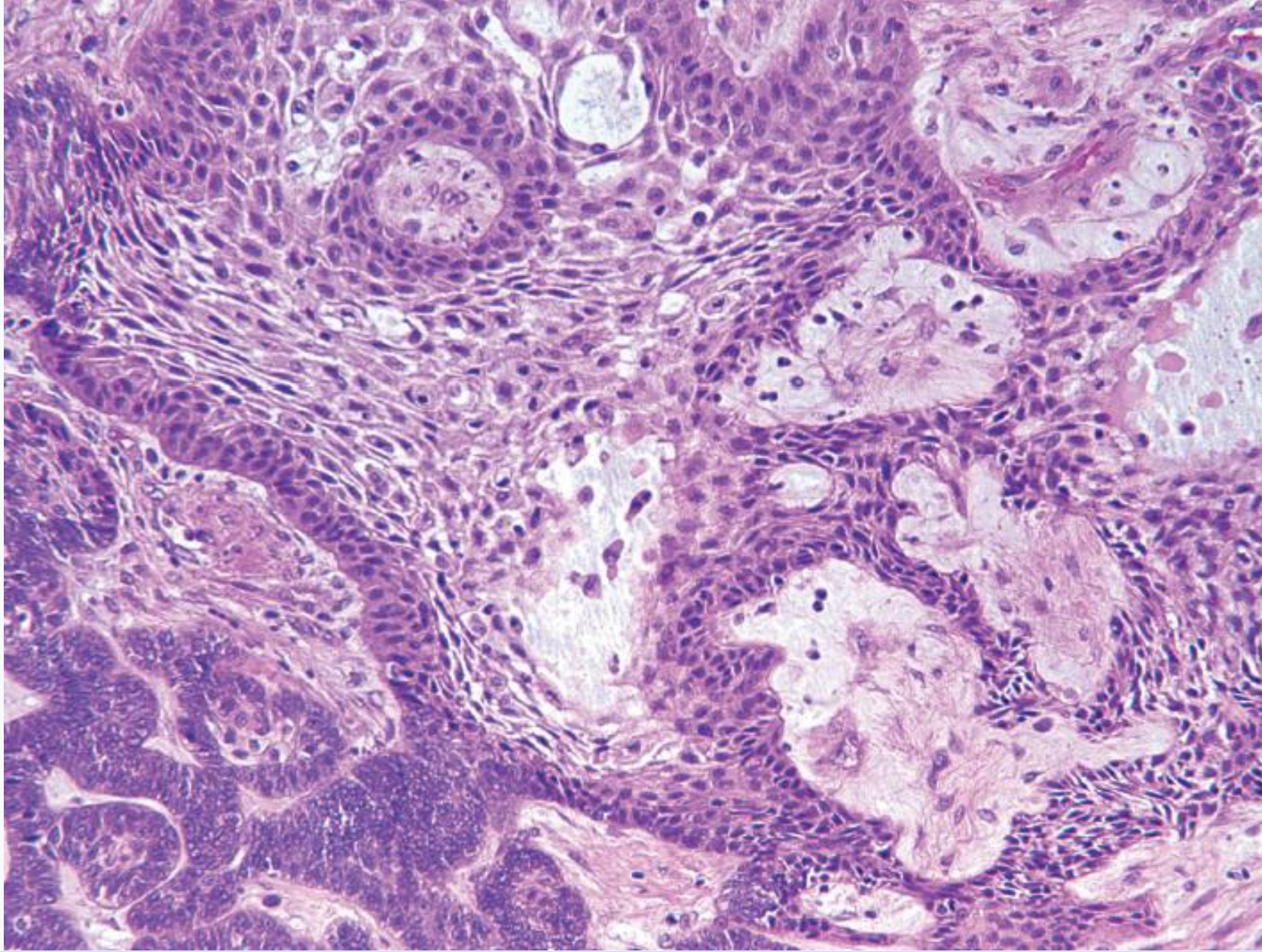


# Microscopic features

- Described by Vickers and Gorlin
  - 1) columnar basilar cells
  - 2) palisading of basilar cells
  - 3) polarization of basilar layer nuclei away from the basement membrane
  - 4) hyperchromatism of basal cell nuclei
  - 5) subnuclear vacuolization of the cytoplasm in the basal cells
  - 6) the area above the basal layer displaying loosely aggregated stellate cells that resemble the stratum spinosum of a developing tooth

*6<sup>th</sup> Edition Cummings Otolaryngology*







# Behavior of Ameloblastoma

- Gardner pointed out two main factors that explain the behavior of ameloblastomas:
  - their ability to infiltrate medullary bone and a relative inability to infiltrate compact bone
  - the location of the tumor.
- outer periosteum serve as a back-up barrier to prevent tumor spread

*6<sup>th</sup> Edition Cummings Otolaryngology*

# Overview of the management

- Simple enucleation is not enough
- Challenge is to have clear margins
- Ameloblastoma has high recurrence rate
- General consensus is to have margins that are at least 1 cm past the radiographic limits of the tumor

*6<sup>th</sup> Edition Cummings Otolaryngology*