

Clubfoot (Talipes)

Updated: May 24, 2019

Author: Minoo Patel, MBBS, PhD, MS, FRACS; Chief Editor: Vinod K Panchbhavi, MD, FACS

Overview

Background

Clubfoot (talipes) can be classified as either of the following:

- Postural or positional - Technically, these are not true clubfeet
- Fixed or rigid - These are either flexible (ie, correctable without surgery) or resistant (ie, requiring surgical release, though this is not entirely true according to the Ponseti experience [1, 2, 3])

The Pirani, Goldner, Diméglio, Hospital for Joint Diseases (HJD), and Walker classifications have been published, but no classification system is universally used.[4, 5, 6, 7]

In the past, clubfoot surgery was performed in a way that did not differentiate severity. The same procedure was performed for all patients. Bensahel proposed a more individualized approach (ie, addressing only the structures that require release), in which the surgery is tailored to the deformity. For example, if the forefoot is well corrected and externally rotated, and there is no cavus but there is still significant equinus, a posterior approach alone should suffice (see Treatment).[8]

emedicine

Anatomy

Factors related to bone anatomy include the following:

- Tibia - Slight shortening is possible
- Fibula - Shortening is common
- Talus - In equinus in the ankle mortise, with the body of the talus being in external rotation, the body of the talus is extruded anterolaterally and is uncovered and can be palpated; the neck of the talus is medially deviated and plantarflexed; all relations of the talus to the surrounding bones are abnormal
- Os calcis - Medial rotation and an equinus and adduction deformity are present
- Navicular - The navicular is medially subluxated over the talar head
- Cuboid - The cuboid is medially subluxated over the calcaneal head
- Forefoot - The forefoot is adducted and supinated; severe cases also have cavus with a dropped first metatarsal

Factors related to muscle anatomy include the following:

- Atrophy of the leg muscles, especially in the peroneal group, is seen in clubfeet
- The number of fibers in the muscles is normal, but the fibers are smaller

- The triceps surae, tibialis posterior, flexor digitorum longus (FDL), and flexor hallucis longus (FHL) are contracted
- The calf is smaller and remains so throughout life, even after successful long-lasting correction of the feet

Thickening of the tendon sheaths frequently is present, especially of the tibialis posterior and peroneal sheaths. Contractures of the posterior ankle capsule, subtalar capsule, and talonavicular and calcaneocuboid joint capsules commonly are seen. Contractures are seen in the calcaneofibular, talofibular, (ankle) deltoid, long and short plantar, spring, and bifurcate ligaments. The plantar fascial contracture contributes to the cavus, as does contracture of fascial planes in the foot.

emedicine

Pathophysiology

Various theories of the pathogenesis of clubfeet have been advanced, including the following:

- Arrest of fetal development in the fibular stage
- Defective cartilaginous anlage of the talus
- Neurogenic factors
- Retracting fibrosis
- Anomalous tendon insertions
- Seasonal variations

With respect to neurogenic factors, histochemical abnormalities have been found in posteromedial and peroneal muscle groups of patients with clubfeet. This is postulated to be due to innervation changes in intrauterine life secondary to a neurologic event, such as a stroke leading to mild hemiparesis or paraparesis. This is further supported by a 35% incidence of varus and equinovarus deformity in spina bifida.

Retracting fibrosis (or myofibrosis) may occur secondary to increased fibrous tissue in muscles and ligaments. In fetal and cadaveric studies, Ponseti also found the collagen in all of the ligamentous and tendinous structures (except the Achilles [calcaneal] tendon), and it was very loosely crimped and could be stretched.[2] The Achilles tendon, on the other hand, was made up of tightly crimped collagen and was resistant to stretching. Zimny et al found myoblasts in medial fascia on electron microscopy and postulated that they cause medial contracture.[9]

Inclan proposed that anomalous tendon insertions result in clubfeet.[10] However, other studies have not supported this proposal. It is more likely that the distorted clubfoot anatomy can make it appear that tendon insertions are anomalous.

Robertson noted seasonal variations to be a factor in his epidemiologic studies in developing countries.[11] This coincided with a similar variation in the incidence of poliomyelitis in the children in the community. Clubfoot was therefore proposed to be a sequela of an antenatal polioliike condition. This theory was further supported by motor neuron changes in the anterior horn in the spinal cord of these babies.

emedicine

Etiology

The true etiology of congenital clubfoot is unknown. Most infants who have clubfoot have no identifiable genetic, syndromal, or extrinsic cause.[12]

Extrinsic associations include teratogenic agents (eg, sodium aminopterin), oligohydramnios, and congenital constriction rings. Genetic associations include mendelian inheritance (eg, diastrophic dwarfism; autosomal recessive pattern of clubfoot inheritance).

Cytogenetic abnormalities (eg, congenital talipes equinovarus [CTEV]) can be seen in syndromes involving chromosomal

deletion. It has been proposed that idiopathic CTEV in otherwise healthy infants is the result of a multifactorial system of inheritance.[13] Evidence for this is as follows:

- Incidence in the general population is 1 per 1000 live births
- Incidence in first-degree relations is approximately 2%
- Incidence in second-degree relations is approximately 0.6%
- If one monozygotic twin has CTEV, the second twin has only a 32% chance of having CTEV

A study by Weymouth et al found that associated promoter variants in HOXA9, TPM1, and TPM2 alter promoter expression, which suggested that they may have a functional role in gene regulation in clubfoot.[14] A major candidate gene has not yet been identified.[15]

eMedicine

Epidemiology

The incidence of clubfoot is approximately 1 case per 1000 live births in the United States. An analysis using data from the EUROCAT network reported that the total prevalence of congenital clubfoot in Europe was 1.13 per 1000 births.[16]

The incidence differs among ethnicities. For example, it is close to 75 cases per 1000 live births in the Polynesian islands, particularly in Tonga.

The male-to-female ratio has been reported to be 2:1. Bilateral involvement is found in 30-50% of cases. A 2017 study by Zions et al found that severity did not differ significantly by either sex or bilaterality, though patients with bilateral clubfoot had a wider range of severity.[17]

There is a 10% chance of a subsequent child being affected if the parents already have a child with a clubfoot.

Parker et al pooled data from several birth defects surveillance programs (6139 cases of clubfoot) to better estimate the prevalence of clubfoot and investigate its risk factors.[12] The overall prevalence of clubfoot was 1.29 per 1000 live births, with figures of 1.38 among non-Hispanic whites, 1.30 among Hispanics, and 1.14 among non-Hispanic blacks or African Americans. Maternal age, parity, education, and marital status were significantly associated with clubfoot, along with maternal smoking and diabetes.

eMedicine

Prognosis

Approximately 50% of clubfeet in newborns can be corrected nonoperatively. Ponseti reported an 89% success rate using his technique (including an Achilles tenotomy); others have reported success rates of 10-35%. One study analyzed the correction progression of patients with idiopathic clubfeet after the Ponseti technique.[18] The data indicated that successive castings resulted in reduced cavus and medial crease with a gradual correction of midfoot rotation, adduction, and heel varus. Interestingly, heel equinus improved concurrent with midfoot variables and also with final casting.

Most series have reported 75-90% satisfactory results of operative treatment (appearance and function of the foot). The amount of motion in the joints of the foot and ankle correlates with the degree of patient satisfaction.[19, 20, 21]

Satisfactory results were obtained in 81% of cases, and the range of ankle movement was a major factor in determining the functional result, which again was influenced by the degree of talar dome flattening (suggesting that the primary bone deformity present at birth dictates the eventual result of treatment). In all, 44% of patients had no dorsiflexion beyond neutral, and 38% of patients required further surgery (nearly two thirds of these were bony procedures).

Recurrence rates of deformity were reported at around 25%, with a range of 10-50%. Menelaus reported a 38%

recurrence rate.[22, 23]

The best results were obtained with children older than 3-4 months with a foot large enough to allow the procedure to be performed without compromise (>8 cm, as specified by Simons[24, 25]). The age at operation is directly related to the result. Less-than-satisfactory results may be associated with overcorrection, which occurs in approximately 15% of cases.

Previous surgery seems to have a deleterious effect on the result.

Steinman et al compared the Ponseti and French functional methods for idiopathic clubfeet (265 feet [176 patients] by the Ponseti method; 119 feet [80 patients] by the French functional method).[26] The study showed that although there was a trend toward improved results with the Ponseti method, the difference was not significant. Parents chose the Ponseti method twice as often as the French functional method. Initial correction rates were 94.4% for the Ponseti method and 95% for the French functional method.

Relapses occurred in 37% of the Ponseti-method feet, and in a third of these cases, further nonoperative treatment was successful; however, surgical treatment was necessary for the other two thirds.[26] Relapses occurred in 29% of the feet treated by the French functional method; surgical intervention was necessary in all those cases. At the latest follow-up, outcomes with the Ponseti method were good in 72% of cases, fair in 12%, and poor in 16%. For the French functional method, outcomes were good in 67%, fair in 17%, and poor in 16%.

In a controlled study of 164 patients (238 feet), Jeans et al compared the Ponseti method (n = 122) with the French physiotherapy (PT) method (n = 116) in terms of pedobarographic findings at age 5 years.[27] The only significant difference noted between the two groups was that the PT group had significantly less medial movement of the center of pressure (COP) line. Plantar pressures in the hindfoot and first metatarsal regions were decreased in both groups as compared with control subjects and increased in the midfoot and lateral forefoot regions. Mild residual deformity remained even though clinically successful outcomes were achieved.

Parada et al reviewed the safety of general anesthesia in infants who underwent percutaneous tendoachilles tenotomy. The procedure was performed in 137 patients (182 tenotomies). Of the tenotomies, 92 were unilateral and 45 bilateral. No complications related to anesthesia were identified, and nearly all patients were discharged on the day of surgery.[28]

Pavone et al achieved good/excellent outcomes in 96% of the 82 patients with 114 congenital clubfeet treated with the Ponseti method from 2004 through 2010, with follow-up through 2011.[29]

A two-institution review by Miller et al found that strict adherence to the Ponseti method in nonoperative treatment of isolated clubfoot, as opposed to more flexible adherence, was associated with improved outcome in the form of a reduced risk of subsequent unplanned surgical intervention.[30]

In a cross-sectional study of postcorrection brace wear over a 3-month period in 48 patients in four age-based groups (6-12 months, >1 to 2 years, >2 to 3 years, and >3 to 4 years) who were treated for idiopathic clubfoot, Sangiorgio et al found that patients who wore the brace for a mean of 8 hours daily had significantly lower relapse rates than those who wore the brace for a mean of 5 hours daily.[31]

Jeans et al assessed functional outcomes, at age 10 years, in 175 children (263 feet) initially treated nonoperatively for clubfoot with either the Ponseti or the French PT method and compared outcomes in feet that had undergone only nonoperative treatment with those that required subsequent surgery.[32] They found that clubfeet treated without surgery had better ankle power and isokinetic strength than those that underwent intra-articular surgery for residual deformity or recurrence. Compared with controls, both nonoperatively and surgically treated clubfeet had significant limitations in ankle plantarflexion, resulting in decreased range of motion, moment, and power.

emedicine

Presentation

History and Physical Examination

Seek a detailed family history of clubfoot or neuromuscular disorders, and perform a general examination to identify any other abnormalities. Examine the feet with the child prone, with the plantar aspect of the feet visualized, and supine to evaluate internal rotation and varus. If the child can stand, determine whether the foot is plantigrade, whether the heel is bearing weight, and whether it is in varus, valgus, or neutral.

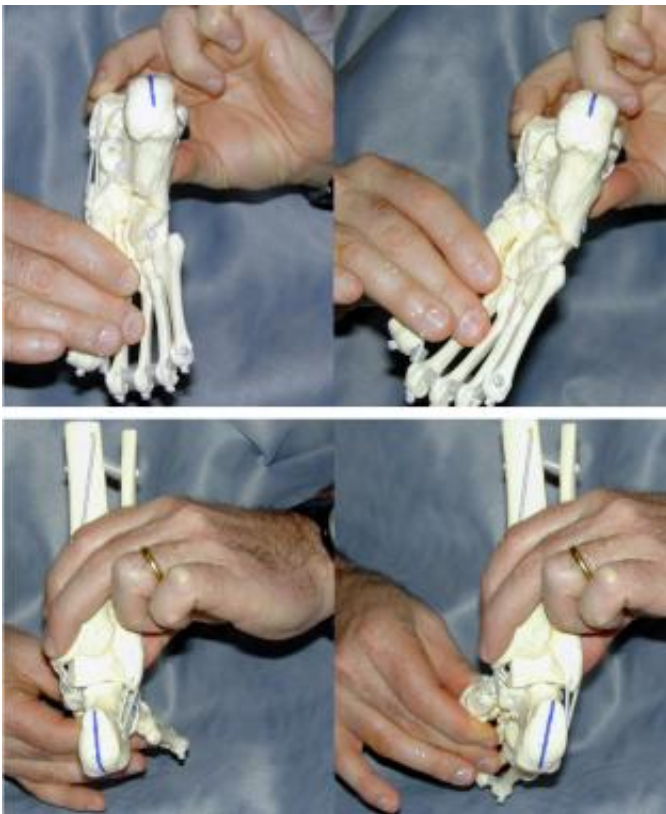
Similar deformities are seen with myelomeningocele and arthrogyrosis. Therefore, always examine for these associated conditions. The ankle is in equinus, and the foot is supinated (varus) and adducted (a normal infant foot usually can be dorsiflexed and everted, so that the foot touches the anterior tibia). Dorsiflexion beyond 90° is not possible.

The navicular is displaced medially, as is the cuboid. Contractures of the medial plantar soft tissues are present. Not only is the calcaneus in a position of equinus, but also the anterior aspect is rotated medially and the posterior aspect laterally.

The heel is small and empty. The heel feels soft to the touch (akin to the feel of the cheeks). As the treatment progresses, it fills in and develops a firmer feel (akin to the feel of the nose or of the chin).

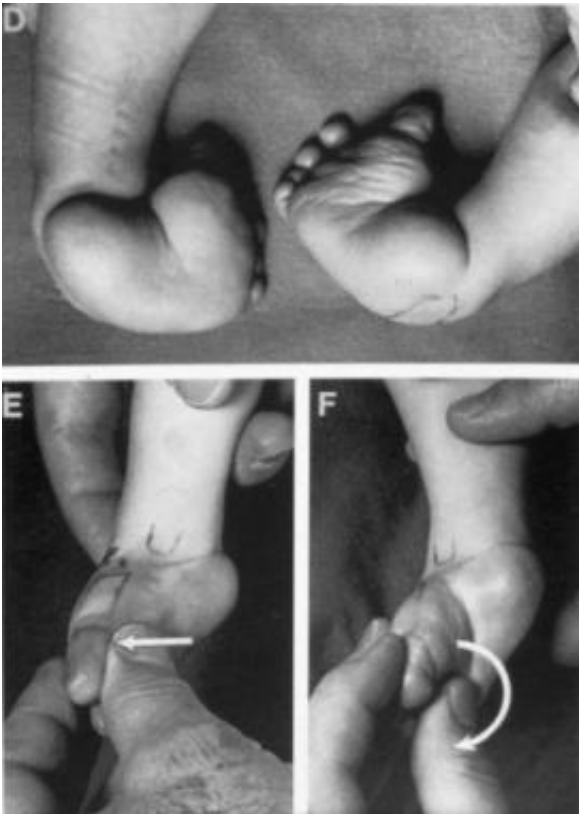
The talar neck is easily palpable in the sinus tarsi as it is uncovered laterally. Normally, this is covered by the navicular, and the talar body is in the mortise. The medial malleolus is difficult to palpate and is often in contact with the navicular. The normal navicular-malleolar interval is diminished.

The hindfoot is supinated, but the foot is often in a position of pronation relative to the hindfoot. (See the image below.) The first ray often drops to create a position of cavus. The Ponseti method of closed management of clubfeet through manipulations and casting describes the elevation of the first metatarsal as a first step, even if it means seemingly exacerbating the supination of the foot.

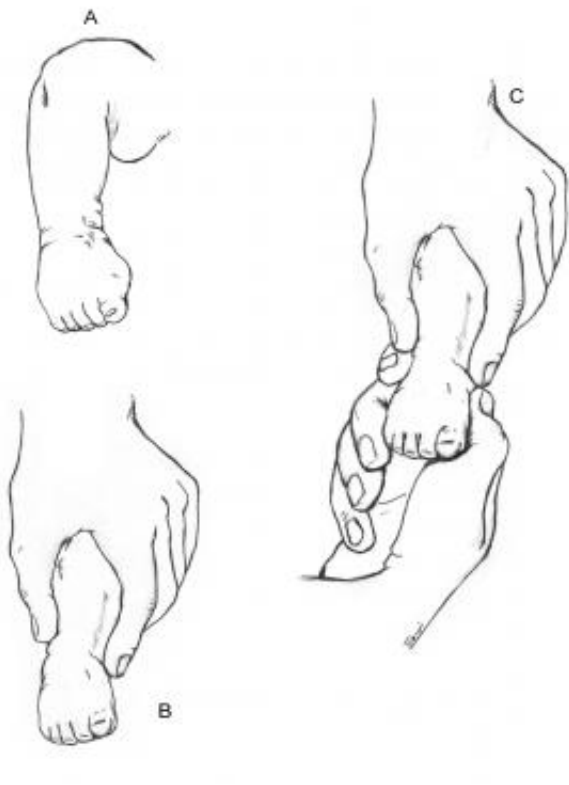


Spontaneous correction of the hind foot varus by abducting the forefoot and allowing the calcaneum to freely rotate under the talus.

The tibia often has internal torsion. This assumes special importance in the casting management of clubfeet, where care should be taken to rotate the feet into abduction, avoiding spurious tibial rotation through the knee. (See the images below.) Even after correction, the foot often remains short and the calf thin.



Never forcibly evert or pronate the foot during clubfoot casting.



Traditional manipulation and casting methods fail, as they do not allow the free rotation of the calcaneum and the talus.

Workup

Imaging Studies

Imaging studies generally are not required to understand the nature or the severity of the deformity. Radiography, however, provides a useful baseline before and after surgical correction of the feet, closed Achilles tenotomy, or a limited posterior release. Radiographs show the true gain in foot (ankle) dorsiflexion and confirm the appearance of an iatrogenic rockerbottom foot should one result. Occasionally, radiographs are necessary to diagnose clubfeet associated with tibial hemimelias.

Radiography

Talocalcaneal parallelism is the radiographic feature of clubfoot (talipes). Simulated weightbearing x-rays are used for infants who have not commenced walking. Positioning for foot x-rays is very important. The anteroposterior (AP) view is taken with the foot in 30° of plantarflexion and the tube at 30° from vertical. The lateral view is taken with the foot in 30° of plantarflexion.

AP and lateral views also can be taken in full dorsiflexion and plantarflexion. This is especially important in measuring the total amount of dorsiflexion achieved at the end of treatment, as well as the relative positions of the talus and calcaneum.

Measure the talocalcaneal angle in the AP and lateral films. AP lines are drawn through the center of the long axis of the talus (parallel to the medial border) and through the long axis of the calcaneum (parallel to the lateral border), and they usually subtend an angle of 25-40°. Any angle less than 20° is considered abnormal.

The AP talocalcaneal lines are almost parallel in clubfeet. As the feet correct with casting or surgery, the calcaneus rotates externally, and the talus reciprocally also derotates to a lesser degree to give a convergent talocalcaneal angle.

Lateral lines are drawn through the midpoint of the head and body of the talus and along the bottom of the calcaneum, usually 35-50°. Clubfoot ranges between 35° and -10°.

The lateral talocalcaneal lines are almost parallel in clubfeet. As the feet correct with casting or surgery, the calcaneum dorsiflexes relative to the talus to give a convergent talocalcaneal angle.

These two angles, AP and lateral, are added to derive the talocalcaneal index, which in a corrected foot should be more than 40°.

The AP and lateral talar lines normally pass through the center of the navicular and the first metatarsal.

In older children, a flat-top talus can be demonstrated radiologically if the talus is sufficiently calcified, but care is required for positioning of the foot.

A lateral film with the foot held in maximal dorsiflexion is the most reliable method of diagnosing an uncorrected clubfoot; the absence of calcaneal dorsiflexion is evidence that the calcaneus is still locked in varus angulation under the talus.

Treatment

Approach Considerations

Although it is sometimes recommended that idiopathic clubfoot (talipes) be treated as soon as possible, this condition does not constitute an orthopedic emergency.[33]

Traditionally, surgery for clubfoot has been indicated when a plateau has been reached in nonoperative treatment. It has usually been performed when the child is of sufficient size to allow recognition of the anatomy. No specific contraindications for surgery exist, though the child's size dictates that surgery is best performed at approximately age 6 months.

With greater acceptance of the Ponseti conservative technique, surgery has come to be seen to be a contentious issue. Surgery for clubfeet is not the only standard of care.[34]

eMedicine

Nonoperative Therapy

The aims of nonoperative therapy for clubfoot are to correct the deformity early and fully and to maintain the correction until growth stops.

Traditionally, two categories of clubfeet are identified, as follows:

- Easy or correctable clubfeet - These are readily corrected with manipulation, casting, and splintage alone
- Resistant clubfeet - These respond poorly to splinting and relapse quickly after seemingly successful manipulative treatment; they require early operative management and are said to be associated with a thin calf and a small high heel.

The Pirani scoring system, devised by Shafiq Pirani, MD, of Vancouver, BC, consists of six categories, three in the hindfoot and three in the midfoot, as follows:

- Curvature of the lateral border (CLB) of the foot
- Medial crease (MC)
- Uncovering of the lateral head of the talus (LHT)
- Posterior crease (PC)
- Emptiness of the heel (EH)
- Degree of dorsiflexion (DF)

The first three (CLB, MC, and LHT) constitute the midfoot score, and the last three (PC, EH, and DF) constitute the hindfoot score.[4, 35] Each category is scored as 0, 0.5, or 1. The lowest possible (ie, best) total score for all categories combined is 0, and the highest possible (ie, worst) total score is 6. The Pirani scoring system can be used to identify the severity of the clubfoot and to monitor the correction.

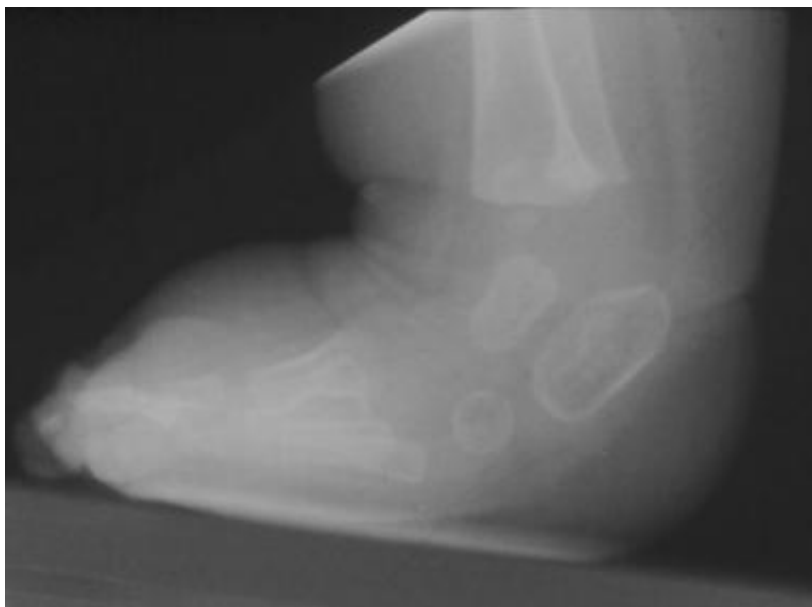It is necessary to provide counsel and advice to parents. They should be reassured that they are in no way responsible for the deformity and that it is unlikely to be reproduced in subsequent pregnancies.

Traditional nonoperative treatment

With traditional nonoperative treatment, splintage begins at 2-3 days after birth. The order of correction is as follows:

- Forefoot adduction
- Forefoot supination
- Equinus

Attempts to correct equinus first may break the foot, producing a rockerbottom foot (see the image below). Force must never be used. Merely bring the foot to the best position obtainable, and maintain this position either by strapping every few days or by changing casting weekly until either full correction is obtained or correction is halted by some irresistible force.



Complications of manipulation treatment. Rockerbottom foot.

The corrected position is maintained for several months. Surgery should be used as soon as it is obvious that conservative treatment is failing (persisting deformity, rockerbottom deformity, or rapid relapse after correction has stopped).

By 6 weeks, it is usually apparent whether the foot is easy or resistant; this is confirmed on x-ray due to the orientation of the bones. Reported success rates for these traditional casting methods are 11-58%.

Ponseti method

This method was developed by Ignacio Ponseti, MD, of the University of Iowa. The premise of the method is based on Ponseti's cadaveric and clinical observations.[1, 3, 26, 36]

A 2014 Cochrane review found this approach to yield significantly better results than either the Kite method or a traditional approach, though the quality of the evidence was not high.[37] A study by Dragoni et al suggested that this approach may be effective for treatment of rigid residual deformity of congenital clubfoot after walking age.[38] A study of 90 children by Liu et al suggested that starting Ponseti treatment between the ages of 28 days and 3 months was associated with fewer casts required, a lower relapse rate, and a lower final international clubfoot study group score (ICFSG) score than starting either earlier or later.[39]

The Ponseti method may be divided into seven steps, as follows.

Step 1

The calcaneal internal rotation (adduction) coupled with plantarflexion is the key deformity. The foot is adducted and plantarflexed at the subtalar joint, and the goal is to abduct the foot and dorsiflex it. In order to achieve correction of the clubfoot, the calcaneum should be allowed to rotate freely under the talus, which also is free to rotate in the ankle mortise.

The correction takes place through the normal arc of the subtalar joint. This is achieved by placing the index finger of the operator on the medial malleolus to stabilize the leg and levering on the thumb placed on the lateral aspect head of the talus while abducting the forefoot in supination. Forcible attempts to correct the heel varus by abducting the forefoot while applying counterpressure at the calcaneocuboid joint prevent the calcaneum from abducting and therefore everting.

Step 2

Foot cavus increases when the forefoot is pronated. If cavus is present, the first step in the manipulation process is to supinate the forefoot by gently lifting the dropped first metatarsal to correct the cavus. Once the cavus is corrected, the forefoot can be abducted as outlined in step 1.

Step 3

Pronation of the foot also causes the calcaneum to jam under the talus. The calcaneum cannot rotate and stays in varus. The cavus increases as outlined in step 2. This results in a bean-shaped foot. At the end of step 1, the foot is maximally abducted but never pronated.

Step 4

The manipulation is carried out in the cast room, with the baby having been fed just before, or even during, the treatment. After the foot is manipulated, a long leg cast is applied to hold the correction.

Initially, the short leg component is applied. The cast should be snug with minimal but adequate padding. The authors paint or spray the limb with tincture of benzoin to allow adherence of the padding to the limb. The authors prefer to apply additional padding strips along the medial and lateral borders to facilitate safe removal of the cast with a cast saw. The cast must incorporate the toes right up to the tips but not squeeze the toes or obliterate the transverse arch. The cast is molded to contour around the heel while abducting the forefoot against counter pressure on the lateral aspect of the head of the talus.

The knee is flexed to 90° for the long leg component of the cast. The parents can soak these casts for 30-45 minutes before removal with a plaster knife. The authors' preferred method is to use the oscillating plaster saw for cast removal. The cast is bivalved and removed. The cast then is reconstituted by coapting the two halves. This allows for monitoring of the progress of the forefoot abduction and, in the later stages, the amount of dorsiflexion or equinus correction.

Step 5

Forcible correction of the equinus (and cavus) by dorsiflexion against a tight Achilles tendon results in a spurious correction through a break in the midfoot, resulting in a rockerbottom foot. The cavus should be separately treated as outlined in step 2, and the equinus should be corrected without causing a midfoot break. It generally takes as many as four to seven casts to achieve maximum foot abduction. The casts are changed weekly. The foot abduction (correction) can be considered adequate when the thigh-foot axis is 60°.

After maximal foot abduction is obtained, most cases require a percutaneous Achilles tenotomy. This is performed in the cast room under aseptic conditions. The local area is anesthetized with a combination of a topical lidocaine preparation (eg, EMLA Cream; AstraZeneca, Wilmington, DE) and minimal local infiltration of lidocaine. The tenotomy is performed through a stab incision with a round-tip (#6400) Beaver blade.

The wound is closed with a single absorbable suture or with adhesive strips. The final cast is applied with the foot in maximum dorsiflexion, and the foot is held in the cast for 2-3 weeks.

Step 6

After the manipulation and casting phase, the feet are fitted with open-toed straight-laced shoes attached to a Dennis Brown bar. The affected foot is abducted (externally rotated) to 70° with the unaffected foot set at 45° of abduction. The shoes also have a heel counter bumper to prevent the heel from slipping out of the shoe. The shoes are worn for 23 hours a day for 3 months and are worn at night and during naps for up to 3 years.

Step 7

In 10-30% of cases, a tibialis anterior tendon transfer to the lateral cuneiform is performed when the child is approximately 3 years of age. This gives lasting correction of the forefoot, preventing metatarsus adductus and foot inversion. This procedure is indicated in a child aged 2-2.5 years with dynamic supination of the foot. Before surgery, cast the foot in a long leg cast for a few weeks to regain the correction.

emedicine

Surgical Therapy

Preparation for surgery

The operating room is kept warm, and a general anesthetic is used. The usual position is supine with the foot resting over the contralateral leg in a figure-four position. Some surgeons prefer the lateral decubitus position or even a prone position. A tourniquet generally is used, and the surgical procedure is performed with the help of optical loupe magnification.

Incision

Options for incisions include the following:

- Cincinnati incision
- Turco curvilinear medial or posteromedial incision

The Cincinnati incision is a transverse incision that extends from the anteromedial (region of navicular-cuneiform joint) to the anterolateral (just distal and medial to the sinus tarsi) aspect of the foot and over the back of the ankle at the level of the tibiotalar joint.[40]

The Turco incision can lead to wound breakdowns, especially at the corner of the vertical and medial limbs.[41, 40] To avoid this problem, some surgeons prefer to use either three separate incisions (posterior vertical, medial, and lateral) or two separate incisions (curvilinear medial and posterolateral).

Any approach should be able to address the release in all quadrants, as follows:

- Plantar - Plantar fascia, abductor hallucis, flexor digitorum brevis (FDB), long and short plantar ligaments
- Medial - Medial structures, tendon sheaths, talonavicular and subtalar release, tibialis posterior, flexor hallucis longus (FHL), and flexor digitorum longus (FDL) lengthening
- Posterior - Ankle and subtalar capsulotomy, especially releasing talofibular and tibiofibular ligaments and calcaneofibular ligaments
- Lateral - Lateral structures, peroneal sheath, calcaneocuboid joint, and completion of talonavicular and subtalar release

Surgical clubfoot release

In the past, clubfoot surgery was performed in a way that did not differentiate severity. The same procedure was performed for all patients. Bensahel proposed a more individualized approach (ie, addressing only the structures that require release). The surgery is tailored to the deformity. For example, if the forefoot is well corrected and externally rotated, if there is no cavus, but if there is still significant equinus, a posterior approach alone should suffice.[42, 43, 8]

Any approach should afford adequate exposure. Structures to be released or lengthened are the following:

- Achilles (calcaneal) tendon
- Tendon sheaths of the muscles crossing the subtalar joint
- Posterior ankle capsule and deltoid ligament
- Inferior tibiofibular ligament
- Fibulocalcaneal ligament
- Capsules of the talonavicular and subtalar joints
- Division of associated ligaments around the subtalar joint
- Plantar fascia and intrinsic muscles

The longitudinal axis of the talus and calcaneum should be separated by about 20° in the lateral projection, and the calcaneal angle should be a right angle to the shaft of the tibia.

The correction is held with wires at the talocalcaneal joint, the talonavicular joint, or both, possibly with a plaster cast. The wound should never be forcibly closed. It can be left open to granulate and heal by secondary intention or even grafted with split-thickness skin grafts.

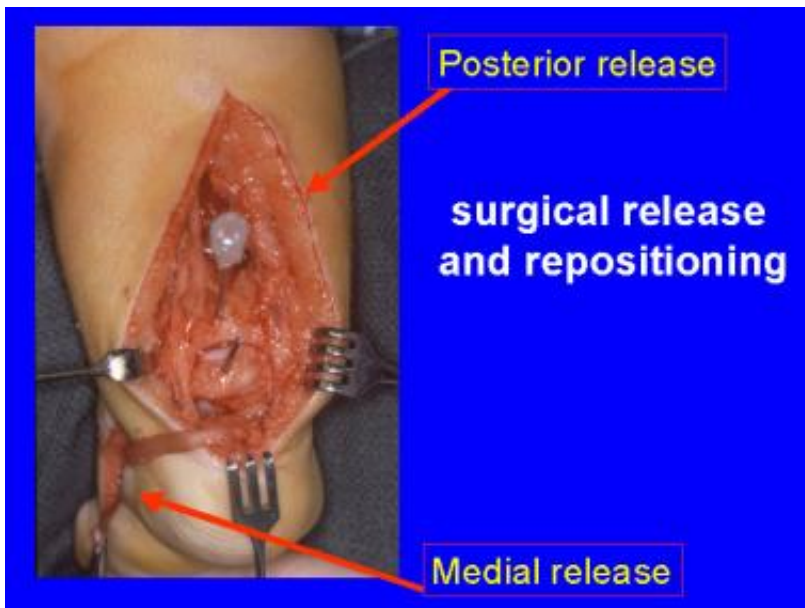Surgical treatment should take into account the age of the patient, as follows:

- In children younger than 5 years, correction can be achieved with soft-tissue procedures
- Children older than 5 years require bony reshaping (eg, dorsolateral wedge excision of the calcaneocuboid joint [Dillwyn Evans procedure] or osteotomy of the calcaneum to correct varus)
- If the child is older than 10 years, lateral wedge tarsectomy or triple fusion (arthrodesis) is required (salvage procedures)

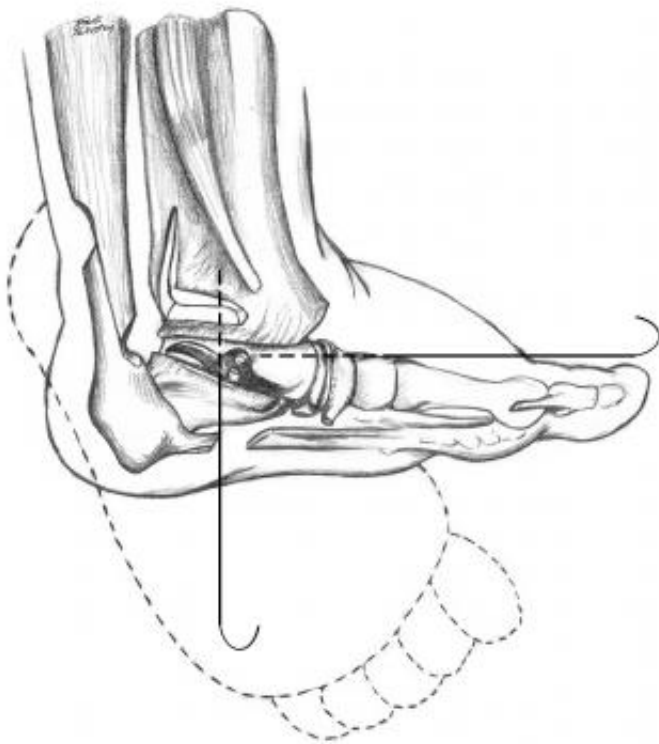
Posterior release steps, in brief, are as follows:

- Longitudinal incision
- Z-lengthened tendocalcaneus
- Identify neurovascular (NV) bundle
- Tendon sheaths of FHL, FDL, and tibialis posterior released; tendons not elongated
- Ankle joint capsule opened; talofibular, calcaneofibular, and deep portion of deltoid ligaments released (blunt dissection)
- Release of distal tibial and fibula ligaments
- Posterior release of the subtalar joint
- With foot held just above neutral, tendocalcaneum is repaired and skin closed
- Plaster-of-Paris cast in corrected position for 4 weeks, followed by splints until maturity

A posteromedial release (Turco procedure[41, 40]) is performed as follows. (See the images below.)



Posteromedial release for clubfoot.



Schematic representation of posteromedial release.

Make a medial incision 8-9 cm long from the base of the first metatarsal to the tendocalcaneum, curving it just inferior to the medial malleolus without undermining skin. Mobilize and expose the tendons of the tibialis posterior, FDL, FHL, Achilles tendon, and posterior NV bundle.

Continuing the incision in the sheaths of FDL and FHL, divide the master knot of Henry beneath the navicular. Divide the spring ligament, detaching it from the sustentaculum tali and the origin of the abductor hallucis. Release the remaining contractures, starting posteriorly. Lengthen the Achilles tendon (Z-plasty), detaching the medial half of the tendon insertion.

Retract the NV bundle and FHL anteriorly to expose the posterior aspect of the ankle and subtalar joints. Then, incise the posterior capsule of the ankle joint under direct visualization, as well as the posterior talofibular ligament (if necessary at this time). Divide the subtalar capsule and calcaneofibular ligament.

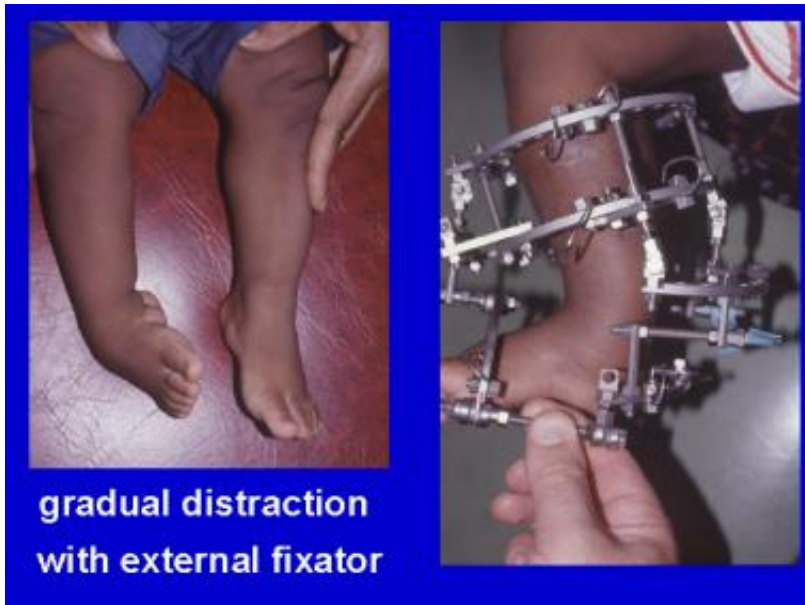Retract the NV bundle posteriorly, and divide the tibiocalcaneal part of the deltoid ligament. Lengthen the tibialis posterior if it is contracted. Open the talonavicular joint and divide its capsule, but avoid damaging the articular surface. Then, release the subtalar ligaments and reduce the navicular onto the head of the talus, which should properly align the other tarsal bones.

Ensure that the relation of the talus to the calcaneus and navicular is correct, and stabilize the foot with Kirschner wires (K-wires). The first K-wire is passed from the dorsum of the foot across the first metatarsal shaft, the medial cuneiform, the navicular, and into the talus. A second wire fixes the subtalar joint, and this should maintain the foot in the corrected position.

Apply an above-the-knee plaster-of-Paris cast, which is changed at 3 weeks and maintained to 6 weeks. The foot is initially held in slight equinus if there is tension on the skin closure, which is corrected at the time of cast change. Splintage is continued for at least 4 months after surgery, and night splints are used for several years.

The Ilizarov correction is used for recurrent clubfeet, especially in conditions such as arthrogryposis.[44, 45, 46, 47] (See the image below.) The calcaneum is held with two opposing olive-tipped wires. The distractor force, in the form of heel-

pushing distractors, must be posteriorly directed to prevent anterior subluxation of the talus in the ankle mortise.



Iliizarov distraction for arthrogryptic clubfoot.

*e*medicine

Postoperative Care

Pay meticulous attention to the wound after surgery. If the skin closure is difficult, it is better to leave the wound open and allow it to granulate for a delayed primary or secondary closure or allow it to heal by granulation tissue. Skin grafts also can be used to cover the defect. The plaster splint should be only lightly applied, and the wound should be inspected regularly.

The transfexion pins usually are removed in 3-6 weeks. The foot requires splintage in appropriate footwear for 6-12 months.

*e*medicine

Complications

Complications of treatment of clubfoot include the following:

- Infection (rare)
- Wound breakdown - Release skin retractors every 30 minutes, and release the tourniquet before closing the wound and applying a cast
- Stiffness and restricted range of motion - Early stiffness correlates with a poor result
- **Avascular necrosis** (AVN) of the talus - A 40% incidence of avascular necrosis of the talus occurs with combined simultaneous medial and lateral release
- Persistent intoeing - This is quite common; it is due not to tibial intorsion but, rather, to insufficient external rotation correction of the subtalar joint

Overcorrection is associated with the following:

- Release of the interosseous ligament of the subtalar joint
- Excess lateral displacement of the navicular on the talus
- Overlengthening of tendon units

For residual deformity following the initial surgery, rule out neurologic causes of recurrence (eg, tethered cord). A residual deformity may be either of the following:

- Dynamic - With residual adductus and supination that are fully correctable passively, treat with split anterior tibial tendon transfer [48]
- Fixed - If scarring is not excessive and the patient is younger than 5 years, repeat the release; if the patient is older than 5 years, a bony procedure to straighten the lateral border of the foot is required

Options to correct adductus are as follows:

- Metatarsal osteotomy - This operation creates a secondary deformity to compensate for a primary deformity in the tarsus; it rarely is indicated
- Cuboid decancellation
- Calcaneocuboid fusion - The Dillwyn Evans procedure consists of a medial and posterior release together with excision and fusion of the calcaneocuboid joint [49]; it should be reserved for patients older than 4 years; these two procedures aim to shorten the lateral side of the foot
- Lengthening the medial side of the foot (eg, talar osteotomy) - This is not widely performed; AVN is a risk

Options to correct residual hindfoot deformity are the following:

- Heel varus - Open the medial wedge, or close the lateral wedge; lateral displacement of calcis osteotomy is preferred
- Residual cavus and adductus - Perform a wedge tarsectomy
- Failed feet - Perform a triple arthrodesis

emedicine

Long-Term Monitoring

As small infants with operated clubfeet have grown into heavy adults, they have been prone to painful stiff feet, despite good correction.[50]

Deitz and Cooper published a 30-year follow-up study of patients treated with the Ponseti method.[51] These cases had comparatively pain-free supple feet. The Ponseti method is gaining mainstream acceptance, as evidenced by the emergence of Ponseti clubfeet centers at major teaching hospitals across the United States.

Of the patients who have been monitored over the long term, those who are heavy and those who have jobs involving long periods on their feet (especially performing manual labor) were found to be more likely to have painful feet.[52] This correlated with the trend seen in the general population at large.

Richards et al evaluated the value of standing lateral radiographs of successfully treated idiopathic clubfeet made at 18-24 months of age for predicting late recurrence (211 patients, 312 clubfeet).[53] Patients were younger than 3 months at presentation, had a clinically plantigrade foot at 2 years of age, and were followed for a minimum of 4 years. Radiographs were assessed for talocalcaneal angle and tibio-calcaneal angles by two trained practitioners. These measurements were not found to be helpful in predicting future relapse.

Little et al studied 104 children (172 feet) with the aim of determining whether poor evertor muscle activity on clinical examination could predict recurrence of idiopathic clubfoot at 5-year follow-up (mean, 62 months; range, 41-71) after Ponseti treatment.[54] Of the 104 patients, 76 had good evertor activity and 28 had poor activity; 19 (18.3%) had recurrence that was treated with repeat casting, and 14 (13.5%) required additional surgery after recasting. Recurrence was highly associated with poor evertor activity. The authors suggested that semiquantitative evertor muscle activity

assessment could predict recurrence and should be added to routine clinical assessment to facilitate individualization of treatment.



Contributor Information and Disclosures

Author

Minoo Patel, MBBS, PhD, MS, FRACS Senior Lecturer, Monash University; Director, Centre for Limb Reconstruction and Deformities, Epworth Centre; Chairman, Cabrini Hospital Orthopaedic Surgery Specialty Group; Orthopaedic Adult/Pediatric Surgeon, Epworth Hospital; Fellowship Director, Epworth Kleos Upper Limb and Limb Reconstruction Fellowship; Consulting Adult/Pediatric Orthopedic Surgeon, Department of Orthopedic Surgery, Monash Medical Center, Australia

Minoo Patel, MBBS, PhD, MS, FRACS is a member of the following medical societies: American Academy of Orthopaedic Surgeons, Australian Association of Surgeons, Australian Medical Association, Australian Orthopaedic Association, Royal Australasian College of Surgeons, Orthopaedic Research Society, AO Foundation, Orthopaedics Overseas, Indian Orthopedic Association, Bombay Orthopedic Society, Shoulder and Elbow Society of Australia, Australian Paediatric Orthopaedic Society, Australian Limb Lengthening and Reconstruction Society, Victorian Hand Surgery Society, Victorian Shoulder and Elbow Society

Disclosure: Nothing to disclose.

Coauthor(s)

John Herzenberg, MD, FRCSC Head of Pediatric Orthopedics, Director of International Center for Limb Lengthening, Rubin Institute for Advanced Orthopedics, Sinai Hospital of Baltimore

John Herzenberg, MD, FRCSC is a member of the following medical societies: American Academy for Cerebral Palsy and Developmental Medicine, Pediatric Orthopaedic Society of North America, Limb Lengthening and Reconstruction Society, American Academy of Orthopaedic Surgeons

Disclosure: Received educational grant from Smith and Nephew, EBI, Orthofix for none.

Specialty Editor Board

Francisco Talavera, PharmD, PhD Adjunct Assistant Professor, University of Nebraska Medical Center College of Pharmacy; Editor-in-Chief, Medscape Drug Reference

Disclosure: Received salary from Medscape for employment. for: Medscape.

Chief Editor

Vinod K Panchbhavi, MD, FACS Professor of Orthopedic Surgery, Chief, Division of Foot and Ankle Surgery, Director, Foot and Ankle Fellowship Program, Department of Orthopedics, University of Texas Medical Branch School of Medicine

Vinod K Panchbhavi, MD, FACS is a member of the following medical societies: American Academy of Orthopaedic Surgeons, American College of Surgeons, American Orthopaedic Association, American Orthopaedic Foot and Ankle Society, Orthopaedic Trauma Association, Texas Orthopaedic Association

Disclosure: Serve(d) as a speaker or a member of a speakers bureau for: Styker.

Additional Contributors

John S Early, MD Foot/Ankle Specialist, Texas Orthopaedic Associates, LLP; Co-Director, North Texas Foot and Ankle Fellowship, Baylor University Medical Center

John S Early, MD is a member of the following medical societies: American Academy of Orthopaedic Surgeons, American Medical Association, American Orthopaedic Foot and Ankle Society, Orthopaedic Trauma Association, Texas Medical Association

Disclosure: Received honoraria from AO North America for speaking and teaching; Received consulting fee from Stryker for consulting; Received consulting fee from Biomet for consulting; Received grant/research funds from AO North America for fellowship funding; Received honoraria from MMI inc for speaking and teaching; Received consulting fee from Osteomed for consulting; Received ownership interest from MedHab Inc for management position.

References

1. Docker CE, Lewthwaite S, Kiely NT. Ponseti treatment in the management of clubfoot deformity - a continuing role for paediatric orthopaedic services in secondary care centres. *Ann R Coll Surg Engl*. 2007 Jul. 89 (5):510-2. [Medline].
2. Ippolito E, Ponseti IV. Congenital club foot in the human fetus. A histological study. *J Bone Joint Surg Am*. 1980 Jan. 62 (1):8-22. [Medline].
3. Scher DM. The Ponseti method for treatment of congenital club foot. *Curr Opin Pediatr*. 2006 Feb. 18 (1):22-5. [Medline].
4. Hussain FN. The role of the Pirani scoring system in the management of club foot by the Ponseti method. *J Bone Joint Surg Br*. 2007 Apr. 89 (4):561; author reply 561-2. [Medline].
5. Lejman T, Kowalczyk B. [Results of treatment of congenital clubfoot with modified Goldner's technique]. *Chir Narzadow Ruchu Ortop Pol*. 2002. 67 (4):351-5. [Medline].
6. Diméglio A, Bensahel H, Souchet P, Mazeau P, Bonnet F. Classification of clubfoot. *J Pediatr Orthop B*. 1995. 4 (2):129-36. [Medline].
7. Kaewpornasawan K, Khuntisuk S, Jatunarpit R. Comparison of modified posteromedial release and complete subtalar release in resistant congenital clubfoot: a randomized controlled trial. *J Med Assoc Thai*. 2007 May. 90 (5):936-41. [Medline].
8. Celebi L, Muratli HH, Aksahin E, Yagmurlu MF, Bicimoglu A, Bensahel et al. and International Clubfoot Study Group evaluation of treated clubfoot: assessment of interobserver and intraobserver reliability. *J Pediatr Orthop B*. 2006 Jan. 15 (1):34-6. [Medline].
9. Zimny ML, Willig SJ, Roberts JM, D'Ambrosia RD. An electron microscopic study of the fascia from the medial and lateral sides of clubfoot. *J Pediatr Orthop*. 1985 Sep-Oct. 5 (5):577-81. [Medline].
10. Inclan A. Anomalous tendon insertions in the pathogenesis of club foot. *J Bone Joint Surg Br*. 1958 Jan. 40-B:159.
11. Robertson WW Jr, Corbett D. Congenital clubfoot. Month of conception. *Clin Orthop Relat Res*. 1997 May. 14-8. [Medline].
12. Parker SE, Mai CT, Strickland MJ, Olney RS, Rickard R, Marengo L, et al. Multistate study of the epidemiology of clubfoot. *Birth Defects Res A Clin Mol Teratol*. 2009 Nov. 85 (11):897-904. [Medline].
13. Paton RW, Freemont AJ. A clinicopathological study of idiopathic CTEV. *J R Coll Surg Edinb*. 1993 Apr. 38 (2):108-9. [Medline].
14. Weymouth KS, Blanton SH, Powell T, Patel CV, Savill SA, Hecht JT. Functional Assessment of Clubfoot Associated HOXA9, TPM1, and TPM2 Variants Suggests a Potential Gene Regulation Mechanism. *Clin Orthop Relat Res*. 2016 Jul. 474 (7):1726-35. [Medline].
15. Pavone V, Chisari E, Vescio A, Lucenti L, Sessa G, Testa G. The etiology of idiopathic congenital talipes equinovarus: a systematic review. *J Orthop Surg Res*. 2018 Aug 22. 13 (1):206. [Medline]. [Full Text].
16. Wang H, Barisic I, Loane M, Addor MC, Bailey LM, Gatt M, et al. Congenital clubfoot in Europe: A population-based study. *Am J Med Genet A*. 2019 Apr. 179 (4):595-601. [Medline].
17. Zions LE, Jew MH, Ebramzadeh E, Sangiorgio SN. The Influence of Sex and Laterality on Clubfoot Severity. *J Pediatr Orthop*. 2017 Mar. 37 (2):e129-e133. [Medline].
18. Chaudhry S, Chu A, Labar AS, Sala DA, van Bosse HJ, Lehman WB. Progression of idiopathic clubfoot correction using the Ponseti method. *J Pediatr Orthop B*. 2012 Jan. 21 (1):73-8. [Medline].

19. Morcuende JA, Abbasi D, Dolan LA, Ponseti IV. Results of an accelerated Ponseti protocol for clubfoot. *J Pediatr Orthop*. 2005 Sep-Oct. 25 (5):623-6. [Medline].
20. Ponseti IV. Relapsing clubfoot: causes, prevention, and treatment. *Iowa Orthop J*. 2002. 22:55-6. [Medline].
21. Ponseti IV. Clubfoot management. *J Pediatr Orthop*. 2000 Nov-Dec. 20 (6):699-700. [Medline].
22. Haft GF, Walker CG, Crawford HA. Early clubfoot recurrence after use of the Ponseti method in a New Zealand population. *J Bone Joint Surg Am*. 2007 Mar. 89 (3):487-93. [Medline].
23. Dobbs MB, Corley CL, Morcuende JA, Ponseti IV. Late recurrence of clubfoot deformity: a 45-year followup. *Clin Orthop Relat Res*. 2003 Jun. (411):188-92. [Medline].
24. Simons GW. Calcaneocuboid joint deformity in talipes equinovarus: an overview and update. *J Pediatr Orthop B*. 1995. 4 (1):25-35. [Medline].
25. Simons GW. A standardized method for the radiographic evaluation of clubfeet. *Clin Orthop Relat Res*. 1978 Sep. (135):107-18. [Medline].
26. Steinman S, Richards BS, Faulks S, Kaipus K. A comparison of two nonoperative methods of idiopathic clubfoot correction: the Ponseti method and the French functional (physiotherapy) method. Surgical technique. *J Bone Joint Surg Am*. 2009 Oct 1. 91 Suppl 2:299-312. [Medline].
27. Jeans KA, Erdman AL, Karol LA. Plantar Pressures After Nonoperative Treatment for Clubfoot: Intermediate Follow-up at Age 5 Years. *J Pediatr Orthop*. 2017 Jan. 37 (1):53-58. [Medline].
28. Parada SA, Baird GO, Auffant RA, Tompkins BJ, Caskey PM. Safety of percutaneous tendoachilles tenotomy performed under general anesthesia on infants with idiopathic clubfoot. *J Pediatr Orthop*. 2009 Dec. 29(8):916-9. [Medline].
29. Pavone V, Testa G, Costarella L, Pavone P, Sessa G. Congenital idiopathic talipes equinovarus: an evaluation in infants treated by the Ponseti method. *Eur Rev Med Pharmacol Sci*. 2013 Oct. 17(19):2675-9. [Medline].
30. Miller NH, Carry PM, Mark BJ, Engelman GH, Georgopoulos G, Graham S, et al. Does Strict Adherence to the Ponseti Method Improve Isolated Clubfoot Treatment Outcomes? A Two-institution Review. *Clin Orthop Relat Res*. 2016 Jan. 474 (1):237-43. [Medline].
31. Sangiorgio SN, Ho NC, Morgan RD, Ebramzadeh E, Zions LE. The Objective Measurement of Brace-Use Adherence in the Treatment of Idiopathic Clubfoot. *J Bone Joint Surg Am*. 2016 Oct 5. 98 (19):1598-1605. [Medline].
32. Jeans KA, Karol LA, Erdman AL, Stevens WR Jr. Functional Outcomes Following Treatment for Clubfoot: Ten-Year Follow-up. *J Bone Joint Surg Am*. 2018 Dec 5. 100 (23):2015-2023. [Medline].
33. Zions LE, Sangiorgio SN, Cooper SD, Ebramzadeh E. Does Clubfoot Treatment Need to Begin As Soon As Possible?. *J Pediatr Orthop*. 2016 Sep. 36 (6):558-64. [Medline].
34. Jeans KA, Erdman AL, Jo CH, Karol LA. A Longitudinal Review of Gait Following Treatment for Idiopathic Clubfoot: Gait Analysis at 2 and 5 Years of Age. *J Pediatr Orthop*. 2016 Sep. 36 (6):565-71. [Medline].
35. Dyer PJ, Davis N. The role of the Pirani scoring system in the management of club foot by the Ponseti method. *J Bone Joint Surg Br*. 2006 Aug. 88 (8):1082-4. [Medline].
36. Cummings RJ. The effectiveness of botulinum A toxin as an adjunct to the treatment of clubfeet by the Ponseti method: a randomized, double blind, placebo controlled study. *J Pediatr Orthop*. 2009 Sep. 29 (6):564-9. [Medline].
37. Gray K, Pacey V, Gibbons P, Little D, Burns J. Interventions for congenital talipes equinovarus (clubfoot). *Cochrane Database Syst Rev*. 2014 Aug 12. 8:CD008602. [Medline].
38. Dragoni M, Farsetti P, Vena G, Bellini D, Maglione P, Ippolito E. Ponseti Treatment of Rigid Residual Deformity in Congenital Clubfoot After Walking Age. *J Bone Joint Surg Am*. 2016 Oct 19. 98 (20):1706-1712. [Medline].
39. Liu YB, Li SJ, Zhao L, Yu B, Zhao DH. Timing for Ponseti clubfoot management: does the age matter? 90 children (131 feet) with a mean follow-up of 5 years. *Acta Orthop*. 2018 Dec. 89 (6):662-667. [Medline]. [Full Text].
40. Hsu WK, Bhatia NN, Raskin A, Otsuka NY. Wound complications from idiopathic clubfoot surgery: a comparison of the modified

Turco and the Cincinnati treatment methods. *J Pediatr Orthop*. 2007 Apr-May. 27 (3):329-32. [Medline].

41. Singh BI, Vaishnavi AJ. Modified Turco procedure for treatment of idiopathic clubfoot. *Clin Orthop Relat Res*. 2005 Sep. 438:209-14. [Medline].
42. Bensahel H, Csukonyi Z, Desgrippes Y, Chaumien JP. Surgery in residual clubfoot: one-stage medioposterior release "à la carte". *J Pediatr Orthop*. 1987 Mar-Apr. 7 (2):145-8. [Medline].
43. Bensahel H, Jehanno P, Delaby JP, Themar-Noël C. [Conservative treatment of clubfoot: the Functional Method and its long-term follow-up]. *Acta Orthop Traumatol Turc*. 2006. 40 (2):181-6. [Medline].
44. Ferreira RC, Costa MT, Frizzo GG, Santin RA. Correction of severe recurrent clubfoot using a simplified setting of the Ilizarov device. *Foot Ankle Int*. 2007 May. 28 (5):557-68. [Medline].
45. Freedman JA, Watts H, Otsuka NY. The Ilizarov method for the treatment of resistant clubfoot: is it an effective solution?. *J Pediatr Orthop*. 2006 Jul-Aug. 26 (4):432-7. [Medline].
46. Ferreira RC, Costa MT, Frizzo GG, Santin RA. Correction of severe recurrent clubfoot using a simplified setting of the Ilizarov device. *Foot Ankle Int*. 2007 May. 28 (5):557-68. [Medline].
47. Gupta P, Bither N. Ilizarov in relapsed clubfoot: a necessary evil?. *J Pediatr Orthop B*. 2013 Nov. 22 (6):589-94. [Medline].
48. Gray K, Burns J, Little D, Bellemore M, Gibbons P. Is tibialis anterior tendon transfer effective for recurrent clubfoot?. *Clin Orthop Relat Res*. 2014 Feb. 472 (2):750-8. [Medline].
49. Graham GP, Dent CM. Dillwyn Evans operation for relapsed club foot. Long-term results. *J Bone Joint Surg Br*. 1992 May. 74 (3):445-8. [Medline].
50. Schlegel UJ, Batal A, Pritsch M, Sobottke R, Roellinghoff M, Eysel P, et al. Functional midterm outcome in 131 consecutive cases of surgical clubfoot treatment. *Arch Orthop Trauma Surg*. 2010 Sep. 130 (9):1077-81. [Medline].
51. Cooper DM, Dietz FR. Treatment of idiopathic clubfoot. A thirty-year follow-up note. *J Bone Joint Surg Am*. 1995 Oct. 77 (10):1477-89. [Medline].
52. Wallander H, Larsson S, Bjönness T, Hansson G. Patient-reported outcome at 62 to 67 years of age in 83 patients treated for congenital clubfoot. *J Bone Joint Surg Br*. 2009 Oct. 91 (10):1316-21. [Medline].
53. Richards BS, Faulks S, Razi O, Moualeu A, Jo CH. Nonoperatively Corrected Clubfoot at Age 2 Years: Radiographs Are Not Helpful in Predicting Future Relapse. *J Bone Joint Surg Am*. 2017 Jan 18. 99 (2):155-160. [Medline].
54. Little Z, Yeo A, Gelfer Y. Poor Evertor Muscle Activity is a Predictor of Recurrence in Idiopathic Clubfoot Treated by the Ponseti Method: A Prospective Longitudinal Study With a 5-Year Follow-up. *J Pediatr Orthop*. 2019 Mar 6. [Medline].