



**VI 23/M**  
**Grand Rounds (preoperative)**  
**February 8, 2019**



# Patient Profile

- VI
- 47/F
- With bronchial asthma, on as needed bronchodilator

# Assessment

- Chronic suppurative otitis media, AS
- s/p canal wall down mastoidectomy, tympanoplasty (New Jeddah Hospital, 2006)
- Allergic rhinitis, mild persistent
- Bronchial asthma, not in exacerbation



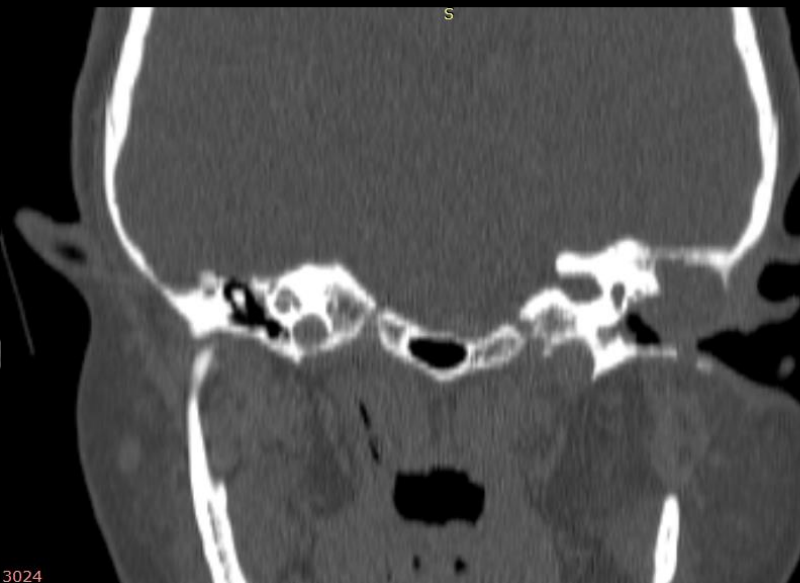
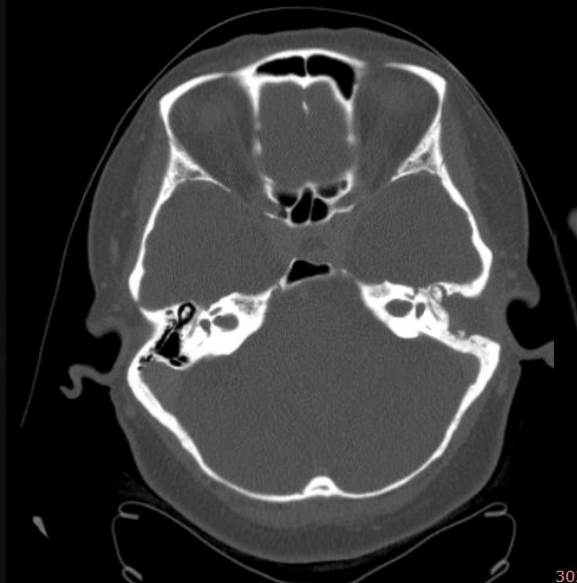
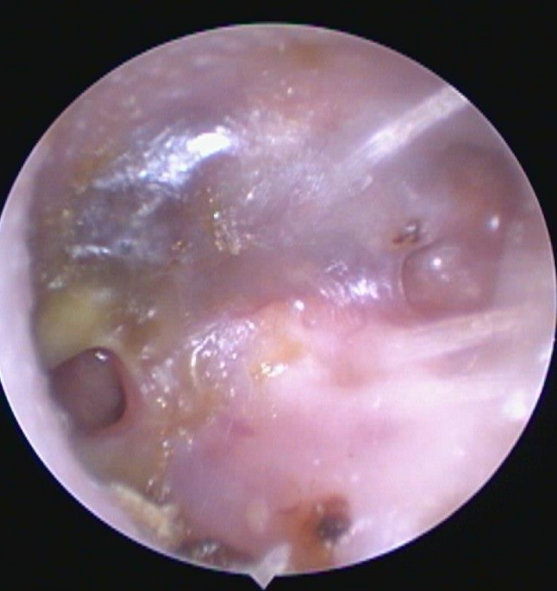# Patient Factors

- Probable allergic rhinitis, mild persistent – not on any medication
- Moderate conductive hearing loss downsloping to profound loss at 8 khz
- 36 dB air-bone gap for the right ear, 18 dB for the left
- Narrow external meatus



# Disease Factors

- No otoscopic signs of cholesteatoma formation
- Current findings not congruent with radiologic findings
- Small graft perforation with suspicious retraction posteriorly
- Tip of mastoid bowl higher than the canal floor (sclerotic mastoid) but with a dependent portion beyond the facial ridge
- Seemingly healthy middle ear mucosa



# General treatment goals:

- Creation of dry, safe ears
- Modification of tympanomastoid cavity to prevent disease recurrence
- Improve hearing



# Indications for revision

- Recurrent or residual cholesteatoma
- Recurrent suppuration
- Recurrent perforation



# Specific treatment goals:

- Explore the left middle ear cleft to rule out residual cholesteatoma and facilitate removal as necessary
- Assess the mobility of the ossicular chain remnants and reconstruct as necessary
- Apply another graft to seal the graft remnant
- Modify the tympanomastoid cavity



# Common causes of failure after mastoidectomy

- Unrecognized and residual squamous epithelium at the time of mastoidectomy
- High facial ridge
- Incomplete posterior bony canal removal
- Deep cavity at mastoid tip
- Inadequate air cell removal
- Incomplete clearance from critical areas:
  - Sinus tympani
  - Hypotympanum
  - Eustachian tube
  - Anterior epitympanum



# Surgical Approaches

- ~~Transcanal~~
- ~~Endaural~~
- Postauricular
  - Extended incision superiorly may be needed to facilitate harvest of temporalis fascia

# Revision tympanomastoidectomy

- Revision surgery should focus on
  - Complete saucerization of the mastoid cavity
  - Exenteration of remaining air cells
  - Lower the posterior canal lateral to the mastoid portion of the facial nerve
  - Removal of cholesteatoma
    - Removal of the malleus, incus, anterior buttress
    - Careful inspections of the aforementioned sites where residual cholesteatoma can accumulate

# Ossiculoplasty

- Assess viability of ossicular remnants
- Assess mobility of stapes footplate
- Reconstruction with the incus remnant can be done if there is sufficient clearance of disease



# Tympanoplasty

- Graft options
  - Temporalis fascia
  - Tragal cartilage
- Placed via underlay technique
- Can be done at time of primary surgery without the need for spacers if mucosa appears healthy

Mundra RK, Sinha R, Agrawal R. Tympanoplasty in subtotal perforation with graft supported by a slice of cartilage: a study with near 100 % results. *Indian J Otolaryngol Head Neck Surg.* 2013;65(Suppl 3):631-5.

# Mastoid obliteration

- Reduce the size of the mastoid cavity
- Options:
  - Musculooperiosteal flaps (if still available)
  - Cartilage
  - Fat
  - Fascia

# Meatoplasty

- Create an opening which will allow easier inspection and cleaning of the mastoid bowl



# Plan

- Revision