



GRAND ROUNDS - January 26, 2018



DEPARTMENT OF OTORHINOLARYNGOLOGY
PHILIPPINE GENERAL HOSPITAL

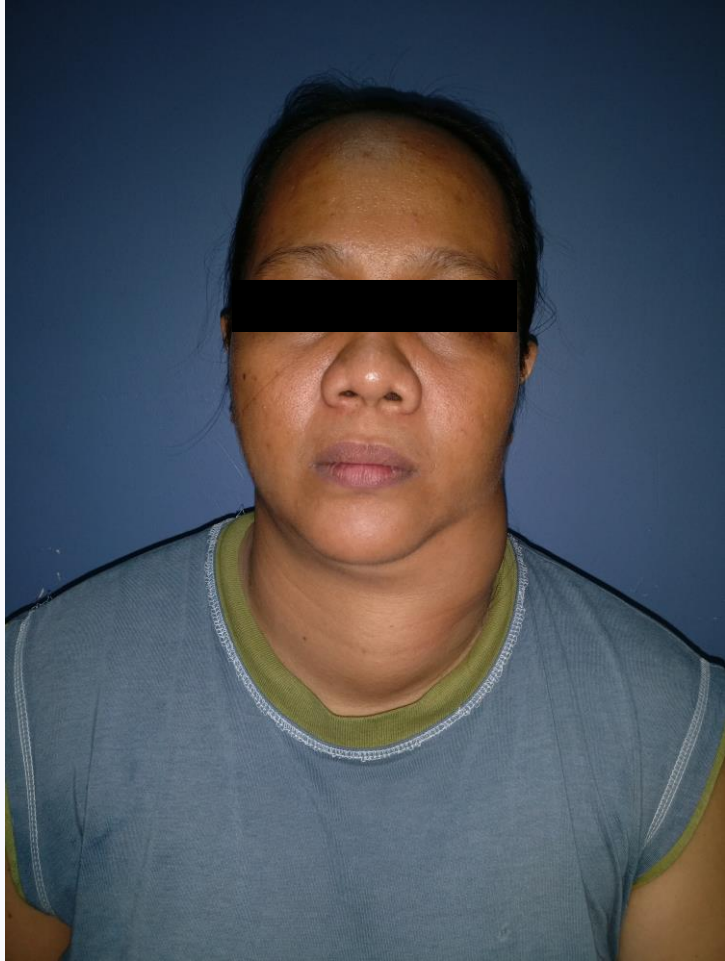VISION

The Department of Otorhinolaryngology shall be an internationally recognized center of excellence in the field of Otorhinolaryngology and Head and Neck Surgery

MISSION

The health needs of the Filipino shall be its prime consideration.

It shall provide excellence and leadership in the different aspects in Otolaryngology – Head and Neck Surgery by teaching, providing exemplary clinical practice and dynamically pursuing relevant researches beneficial to the community in an environment guided by moral, ethical and spiritual values.




General Information

- F.F.
- 40/F
- Single
- Roman Catholic
- Lives in Quezon City

History of Present Illness

18 years prior to admission

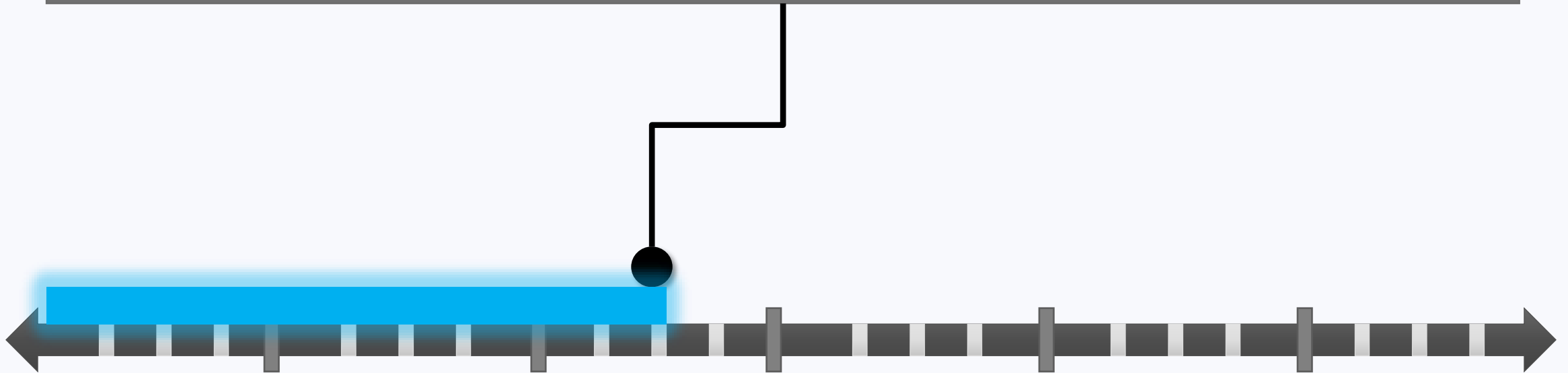
- 2x2 cm soft, irregularly shaped, movable nontender anterior neck mass
 - (-) dysphagia, (-) dyspnea, (-) hoarseness, (-) palpitations, (-) weight changes, (-) tremors, (-) heat/cold intolerance, (-) easy fatigability
- No consult done or meds taken



History of Present Illness

In the interim

- No increase in size of the anterior neck mass
- No appearance of other masses
- No onset of new symptoms



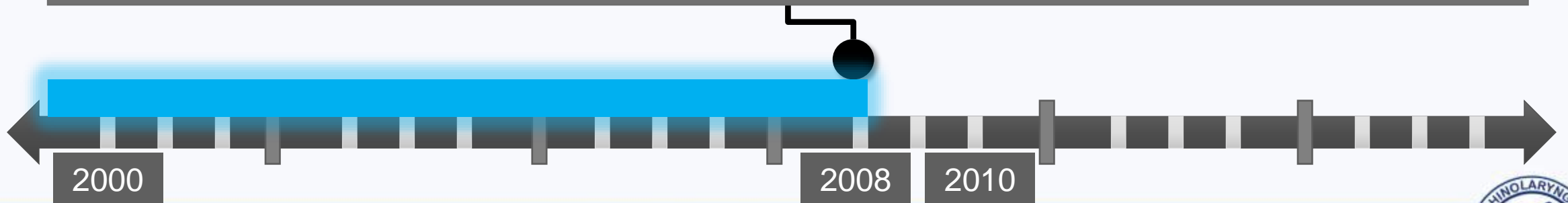
History of Present Illness

10 years prior to admission

- Slight increase in the size of the anterior neck mass, no symptoms
- Unable to consult due to lack of resources

8 years prior to admission

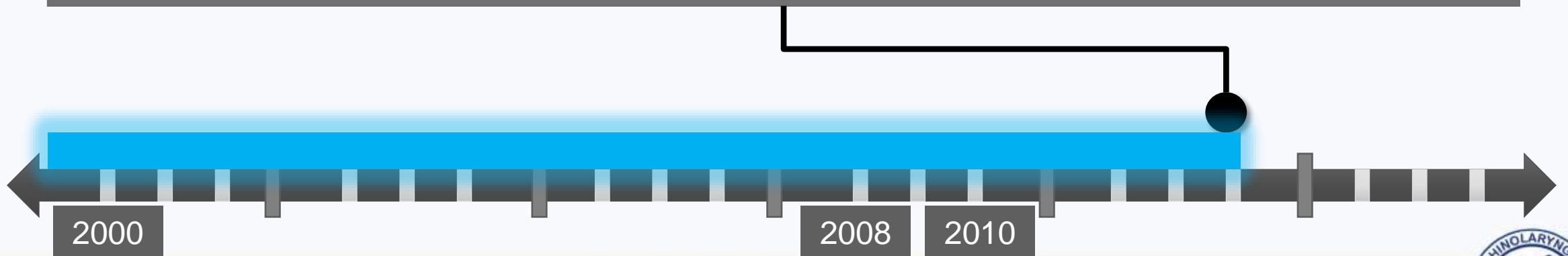
- Consulted with a private physician where no work-up was done
- Assessment: hyperthyroidism
- Plan: methimazole 5mg/tab, 1 tab daily for 3 months with follow-up
- Complied with medication for one month and did not follow up



History of Present Illness

In the interim

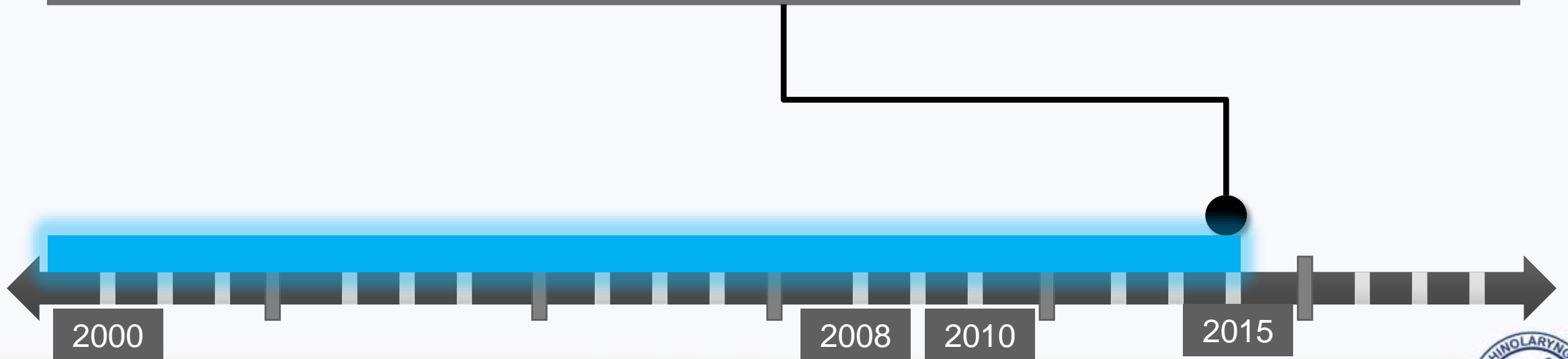
- Gradual increase in the size of the mass but no change in consistency, or pain
- No palpable lymph nodes
- (-) dysphagia, (-) hoarseness, (-) dyspnea, (-) palpitations, (-) easy fatigability, (-) weight changes
- No repeat consult done



History of Present Illness

3 years prior to admission

- Further increase in size of the initial neck mass extending to involve the left side of the neck
- No associated symptoms
- No consult or intake of medication




History of Present Illness

1 year prior to admission

- Increase in mass size, extending to involve the right side of the neck
- Consult with a private physician where FT4 and TSH levels were taken and assessed to be normal
- Advised neck ultrasound and, subsequently, surgery

Neck ultrasound (2/13/2017):

- Bilaterally enlarged multinodular thyroid gland
 - Multiple well-defined solid foci, right lobe
 - Solid masses, left lobe



History of Present Illness

4 months PTA


- Opted to seek a second opinion at PGH and was seen at the ORL OPD where FNAB and FT4 TSH were ordered
 - A> multinodular nontoxic goiter
- Advised admission and surgery

Fine needle aspiration biopsy (10/19/2017):

Bethesda Category II
Cell findings consistent with colloid nodule

FT4 = 10.89

TSH = 0.8508



Review of Systems

(-) fever

(-) headache

(-) dizziness

(-) blurring of vision

(-) epistaxis

(-) nasal congestion

(-) chest pain

(-) cough

(-) abdominal pain

(-) diarrhea/constipation

(-) dysuria

(-) polyuria

(-) nocturia

(-) numbness

(-) edema

Past Medical History

- (-) hypertension
- (-) diabetes
- (-) bronchial asthma
- (-) tuberculosis
- (-) heart disease
- (-) cancer
- (-) liver disease
- (-) kidney disease
- (-) previous surgeries
- (-) allergies

Family Medical History

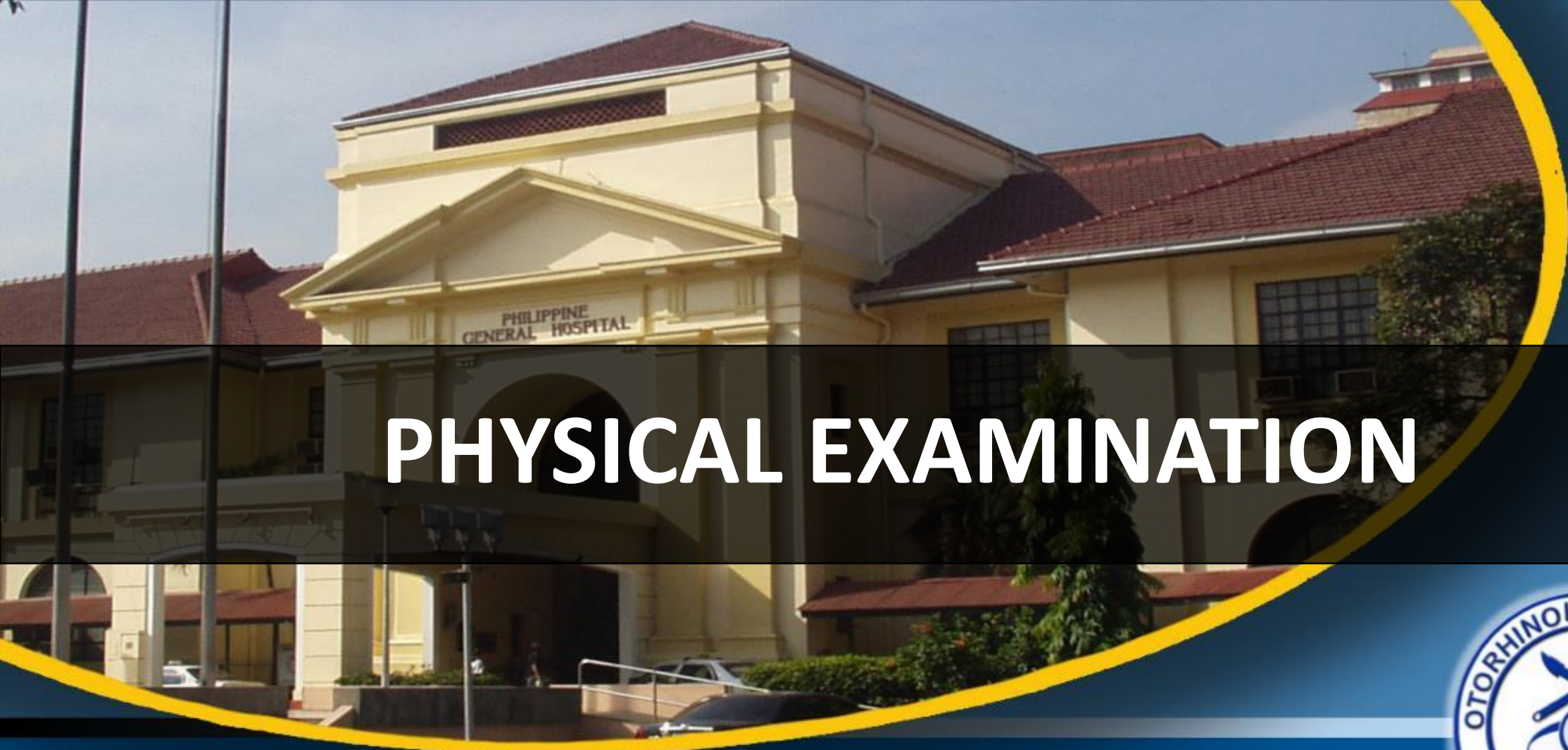
- (+) thyroid disease (sister, paternal grandmother)
- (+) diabetes (father)
- (-) hypertension
- (-) heart disease
- (-) cerebrovascular disease
- (-) bronchial asthma
- (-) tuberculosis
- (-) cancer

Personal and Social History

- Occasional smoker (2 sticks/week)
- Non alcoholic beverage drinker
- Denies illicit drug use
- High school graduate
- Stay at home mom
- 2 sexual partners and cohabits with the current partner

Obstetric History

- Menarche: 12 years old
- Interval: 2-3 months
- Duration: 7 days
- Amount: 3 pads per day
- (-) dysmenorrhea
- G4P4 (4004)
 - Spontaneous vaginal delivery
 - Eldest born in a hospital, three born at home assisted by a midwife
 - No fetomaternal complications



PHYSICAL EXAMINATION

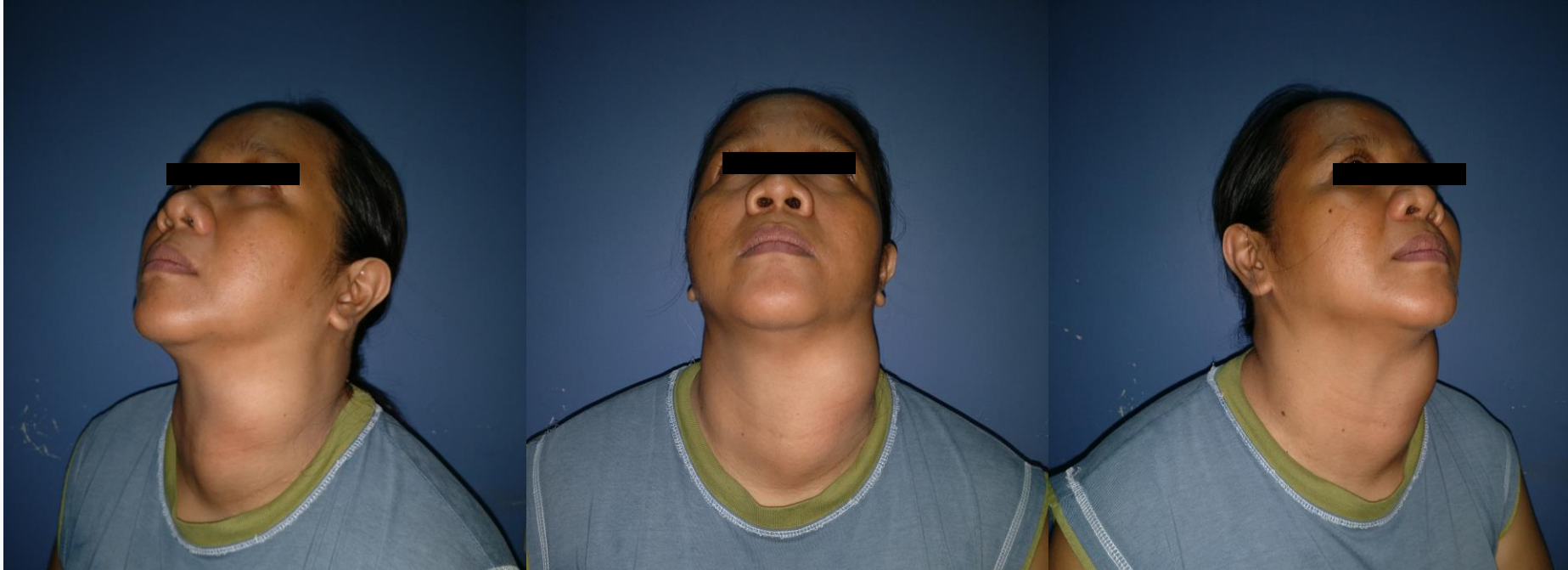

DEPARTMENT OF OTORHINOLARYNGOLOGY
PHILIPPINE GENERAL HOSPITAL

SYSTEMIC PE

- **VITAL SIGNS:** BP 110/80, HR 66, RR 18, Temp 36.7, Ht 150cm, Wt 72.9 kg
- **GENERAL:** awake, coherent, ambulatory, not in cardiorespiratory distress
- **CARDIAC:** adynamic precordium, normal rate with regular rhythm, no murmurs
- **PULMONARY:** equal chest expansion, clear breath sounds, no rhonchi/wheezes/crackles
- **ABDOMEN:** soft abdomen, normoactive bowel sounds, no tenderness
- **EXTREMITIES:** full and equal pulses, pink nail beds, good capillary refill time, no edema
- **SKIN:** no lesions

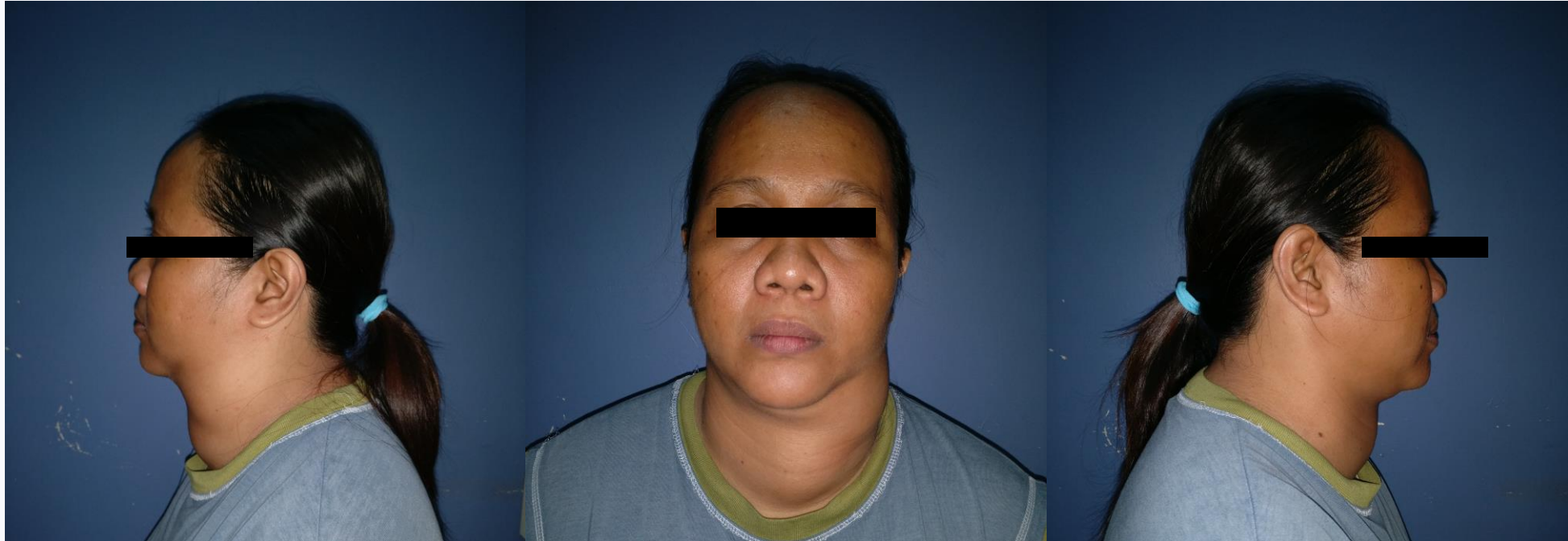HEAD & NECK EXAMINATION



- (+) 7 x 4.5 x 2 cm firm, round, nontender, movable mass at the upper pole of the left lobe of the thyroid
- (+) 10 x 7 x 2 cm firm, irregularly shaped, nontender, movable mass at the mid to lower pole of the left lobe of the thyroid extending into the isthmus
- (+) 4 x 3 x 1 cm soft, irregularly shaped, ill-defined, nontender, movable mass at the middle segment of the right lobe of the thyroid

All masses move with deglutition; no cervical lymphadenopathies

HEAD & NECK EXAMINATION



- (+) 7 x 4.5 x 2 cm firm, round, nontender, movable mass at the upper pole of the left lobe of the thyroid
- (+) 10 x 7 x 2 cm firm, irregularly shaped, nontender, movable mass at the mid to lower pole of the left lobe of the thyroid extending into the isthmus
- (+) 4 x 3 x 1 cm soft, irregularly shaped, ill-defined, nontender movable mass at the middle segment of the right lobe of the thyroid

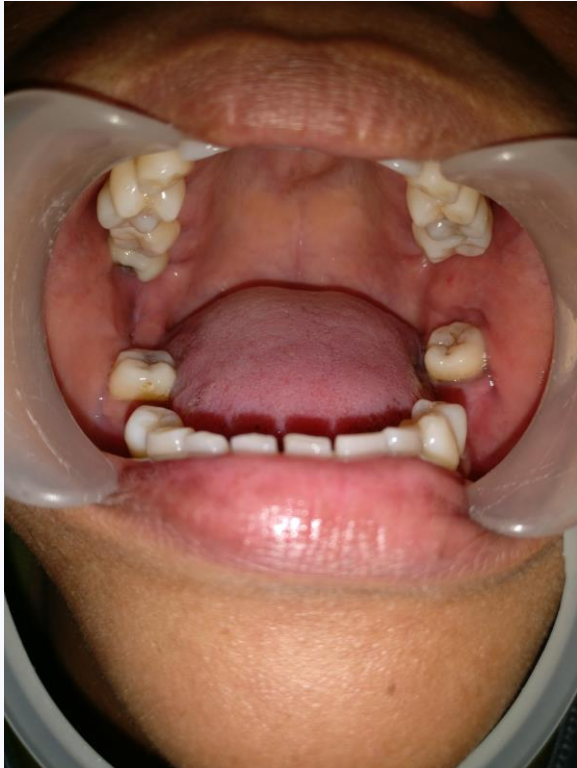All masses move with deglutition; no cervical lymphadenopathies

OTOLOGIC EXAM




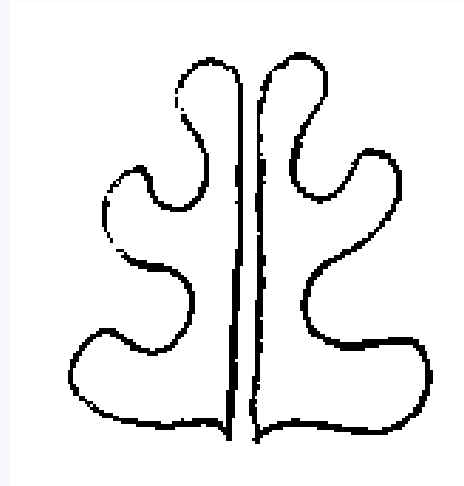
AU: (+) patent EAC, (+) intact TM, (+) cone of light,
(-) erythema, (-) discharge, (-) masses

ORAL CAVITY EXAM




Pink oral mucosa
Tongue and uvula midline
Two missing molars
(-) dental caries, masses, lesions

RHINOSCOPIC EXAM



Midline septum, (-) intranasal masses, discharge

INDIRECT LARYNGOSCOPY



Fully mobile vocal cords



PHILIPPINE
GENERAL HOSPITAL

DIAGNOSTICS



DEPARTMENT OF OTORHINOLARYNGOLOGY
PHILIPPINE GENERAL HOSPITAL

Pertinent Diagnostics

- **ULTRASOUND GUIDED FNAB (Oct, 2017)**
 - Bethesda Category II: consistent with colloid nodule
- **FT4 (1/24/2018): 11.57**
- **TSH (1/24/2018): 0.7331**
- **NECK ULTRASOUND (Feb. 2, 2017)**
 - The right thyroid lobe measures 8.54 x 3.33 x 2.37 cm
 - Multiple well-defined solid foci are seen measuring as follows:
 - Upper pole – 1.25 x 1.08 x 0.95cm, 0.88 x 0.83 x 0.69 cm, and 0.78 x 0.73 x 0.57 cm
 - Midsegment – 0.54 x 0.58 x 0.50 cm and 3.90 x 2.95 x 2.24 cm
 - Lower pole – 1.90 x 1.82 x 1.14 cm and 0.94 x 1.04 x 0.58 cm
 - These foci exhibit peripheral vascular flow

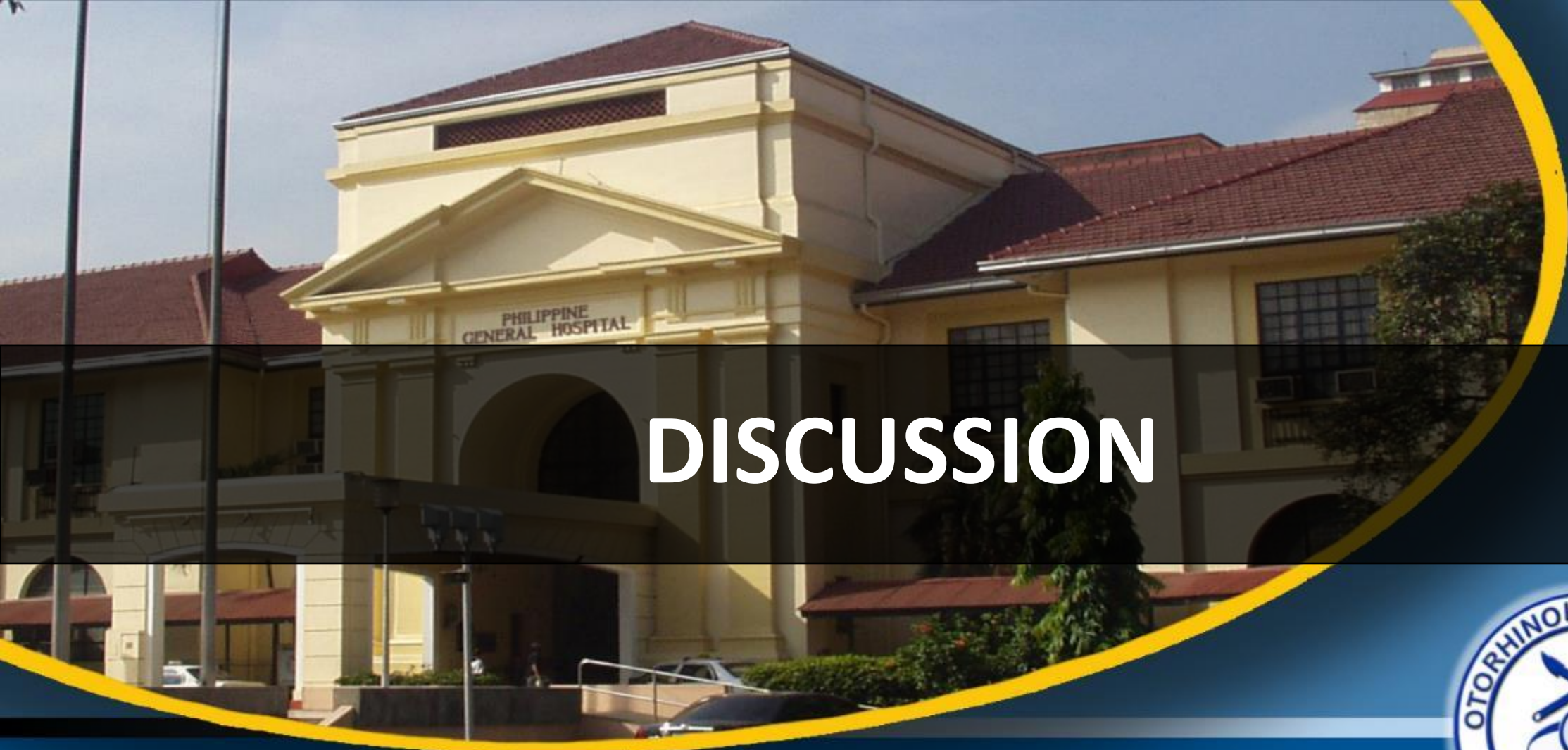Pertinent Diagnostics

- **NECK ULTRASOUND (Feb. 2, 2017)**

- The left thyroid lobe measures 13.69 x 8.70 x 5.05 cm
- Solid masses are noted:
 - Upper pole – 5.99 x 5.86 x 4.03 cm
 - Mid segment – 6.93 x 6.49 x 3.98 cm
 - Lower pole – 6.27 x 6.30 x 4.73 cm
- No significant intralesional vascular flow noted within these masses
- The isthmus is thickened and measures 0.63 cm
- Impression: bilaterally enlarged multinodular thyroid gland

Salient points

- This is a case of multinodular nontoxic goiter in a 40/F with an 18 year history of a gradually enlarging thyroid mass and a family history of benign thyroid disease.
- Neck ultrasound revealed multiple solid masses in both thyroid lobes, predominantly on the left with a FNAB Bethesda category II.



PHILIPPINE
GENERAL HOSPITAL

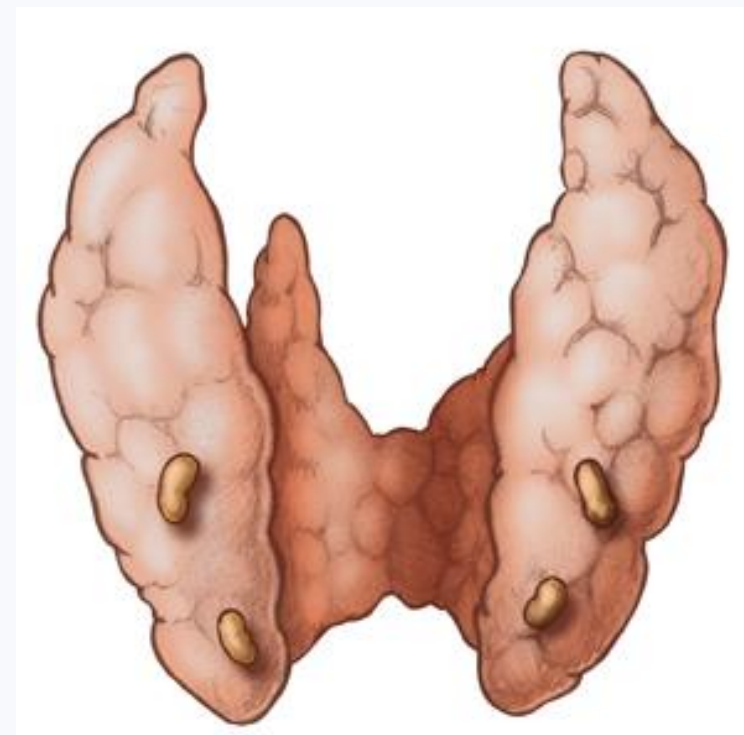DISCUSSION



DEPARTMENT OF OTORHINOLARYNGOLOGY
PHILIPPINE GENERAL HOSPITAL

Thyroid Anatomy

- Two lobes, joined by the isthmus
 - 4 x 1.5 x 2 cm, 15-25 g
 - Pyramidal lobe
- Connected to the cricoid cartilage via the posterior suspensory ligament
- Supplied by the superior and inferior thyroid arteries



Flint, P., Haughey, B., Robbins, K., Thomas, J., Niparko, J., Lund, V. and Lesperance, M. (2014). Cummings Otolaryngology - Head and Neck Surgery. London: Elsevier Health Sciences.

Multinodular Nontoxic Goiter

Epidemiology

- National Nutrition Surveys

- 1987: 3.7%
- 1993: 6.7%

- PhilTiDeS

- 8.9% had goiters
 - 56% diffuse goiter
 - 44% nodular goiter
- 9.11% of those who had normal TFTs had goiters

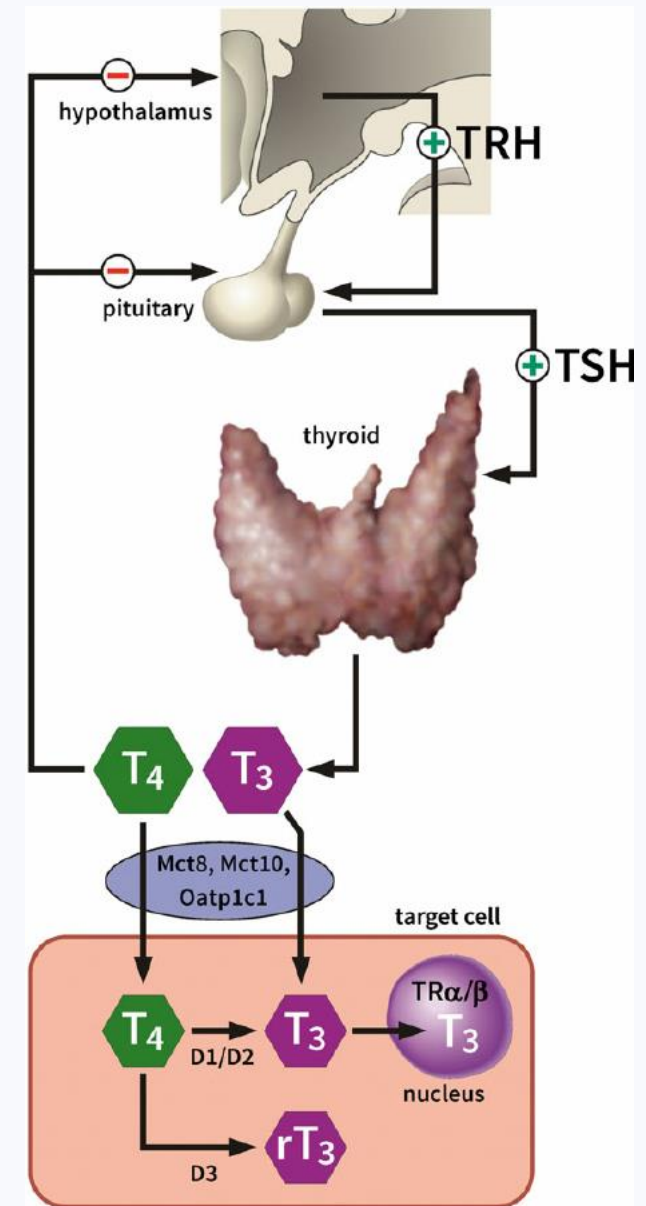
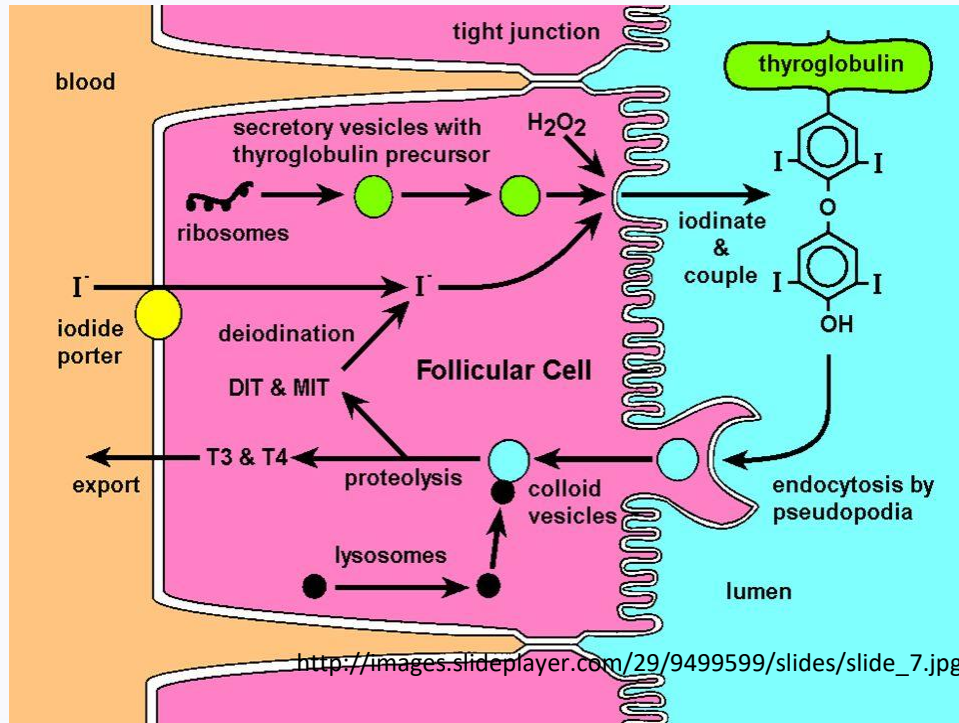
Table 4. Distribution of the sample population according to biochemical status and presence or absence of goiter

Functional status	Total	No goiter	With goiter
Normal	4446	4025 (90.89%)	421 (9.11%)
True Hyperthyroidism	30	14 (47.18%)	16 (52.82%)
Subclinical hyperthyroidism	255	216 (85.39%)	39 (14.61%)
True Hypothyroidism	19	16 (84.32%)	3 (15.68%)
Subclinical hypothyroidism	109	96 (89.30%)	13 (10.7%)
Total	4859	4367 (89.87%)	492 (10.13%)

Carlos-Raboca, J., Jimeno, C., Kho, S., Andag-Silva, A., Jasul, Jr., G., Nicodemus, Jr., N., Cunanan, E., & Duante, C. (2014). The Philippine Thyroid Diseases Study (PhilTiDeS 1): Prevalence of Thyroid Disorders Among Adults in the Philippines. *Journal of the ASEAN Federation of Endocrine Societies*, 27(1), 27. Retrieved from <http://asean-endocrinejournal.org/index.php/JAFES/article/view/9/400>

Etiology

1. Hyperplasia
2. Altered growth and function
3. Increased growth factors



Medeiros-Neto, G. (2016). Multinodular goiter. Retrieved from <http://www.thyroidmanager.org/chapter/multinodular-goiter/>

Primary Factors

- Functional heterogeneity of normal follicular cells, due to genetic and acquisition of new inheritable qualities by replicating epithelial cells
- Gender (women)
- Subsequent functional and structural abnormalities in growing goiters

Secondary Factors

- Elevated TSH (induced by iodine deficiency, natural goitrogens, inborn errors of thyroid hormone synthesis)
- Smoking, stress, certain drugs
- Other thyroid-stimulating factors (IGF-1 and others)
- Endogenous factor (gender)

Medeiros-Neto, G. (2016). Multinodular goiter. Retrieved from <http://www.thyroidmanager.org/chapter/multinodular-goiter/>

Course of the Disease

- Minimal diffuse enlargement noted at adolescence or puberty
- Sudden growth spurt in longstanding anterior neck masses
- Initial consult
 - Presence of the neck mass
 - Found on routine examination by physician
 - Pressure symptoms

Medeiros-Neto, G. (2016). Multinodular goiter. Retrieved from <http://www.thyroidmanager.org/chapter/multinodular-goiter/>

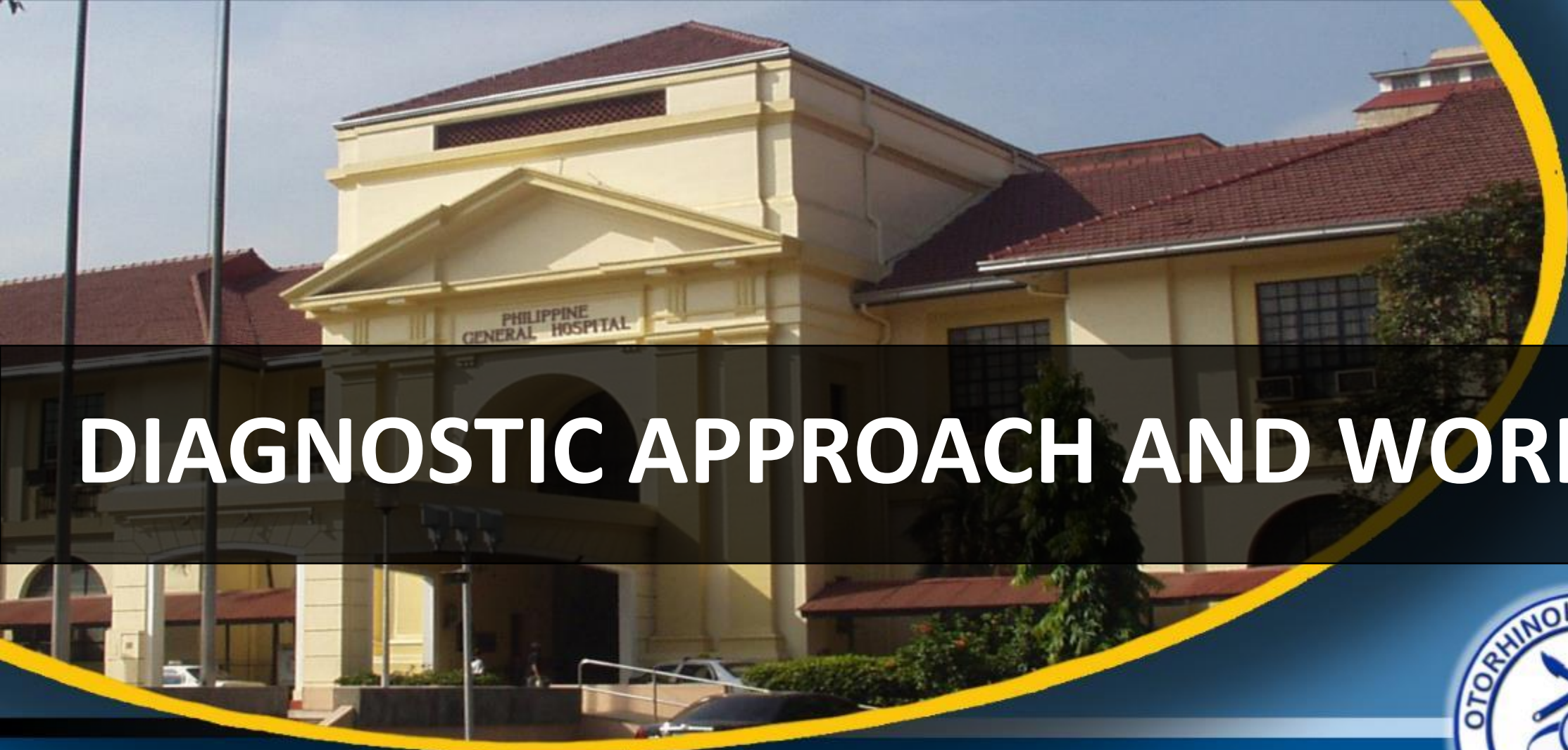Clinical Symptoms in the Diagnosis of MNG

- Often family history of benign thyroid disease
- Slowly growing anterior neck mass
- Uni- or multinodularity on examination
- Enlargement during pregnancy
- Cosmetic complaints
- Asymmetry, tracheal deviation, and/or compression
- Rarely upper airway obstruction, dyspnea, cough, and dysphagia
- Sudden transient pain or enlargement secondary to hemorrhage
- Gradually developing hyperthyroidism
- Superior vena cava obstruction syndrome (rare)
- Recurrent nerve palsy (rare)
- Horner's syndrome (rare)

Medeiros-Neto, G. (2016). Multinodular goiter. Retrieved from <http://www.thyroidmanager.org/chapter/multinodular-goiter/>

ASSESSMENT

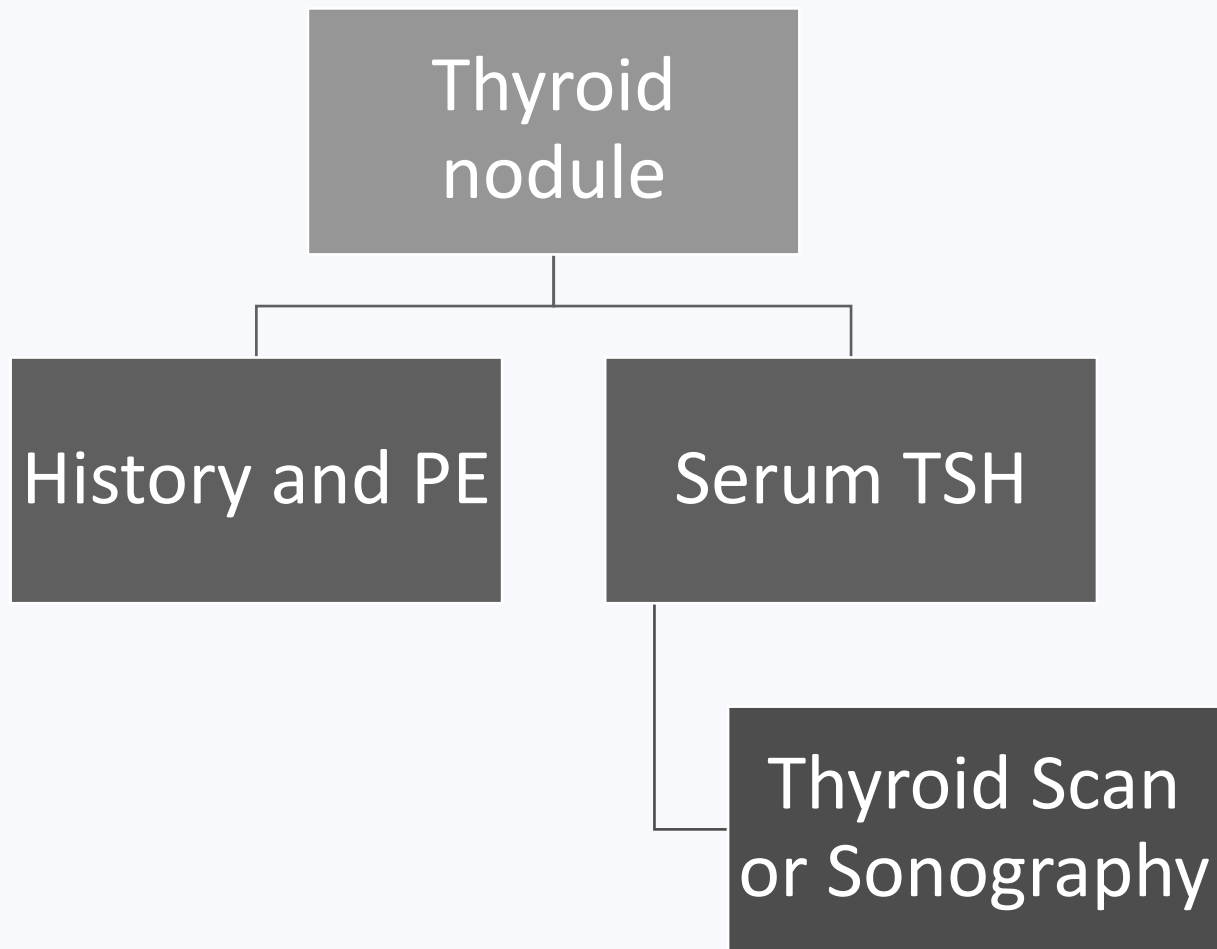
- Multinodular non-toxic goiter



DIAGNOSTIC APPROACH AND WORKUP

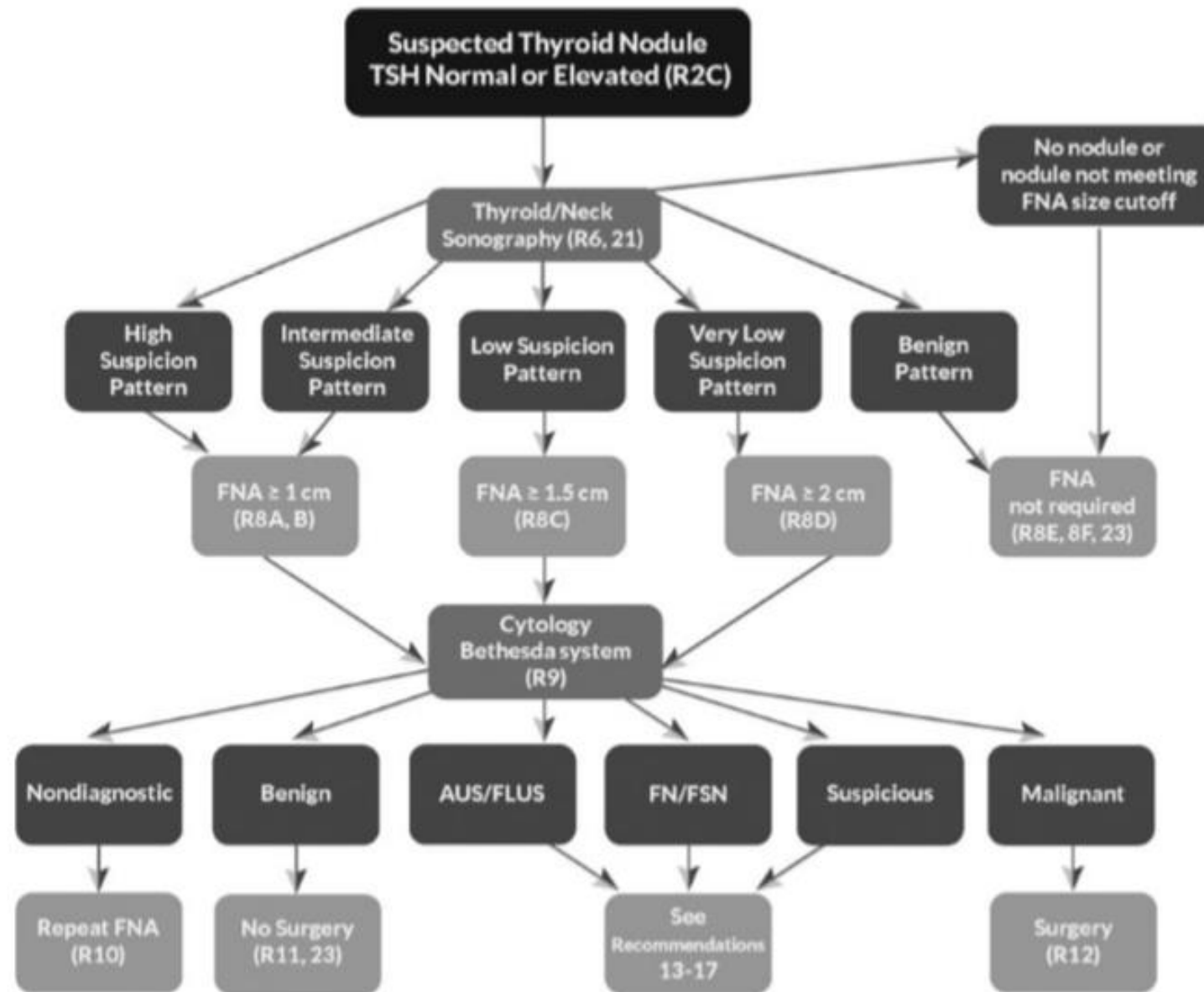


DEPARTMENT OF OTORHINOLARYNGOLOGY
PHILIPPINE GENERAL HOSPITAL



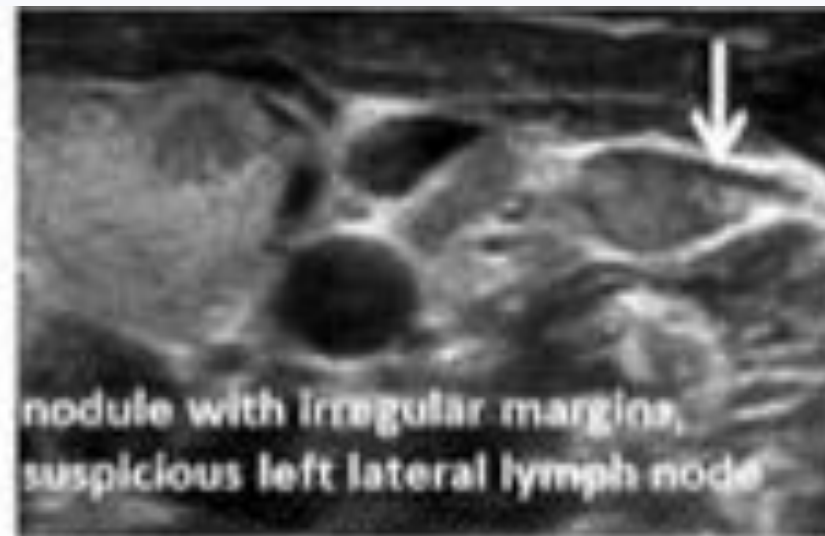
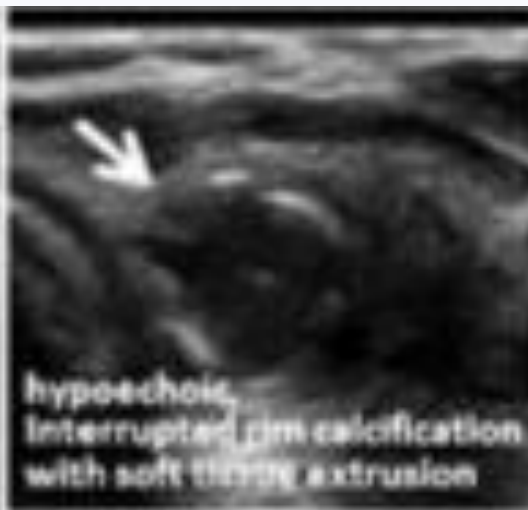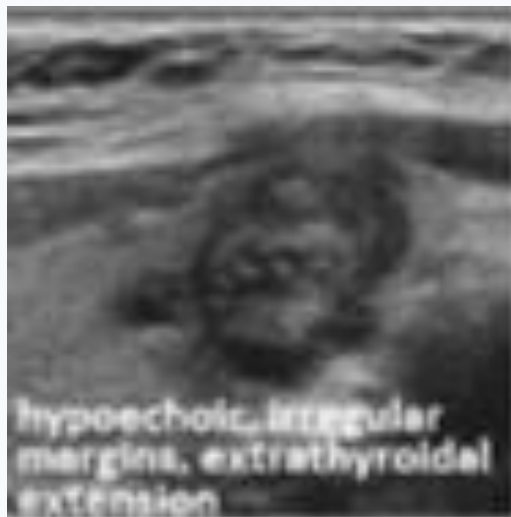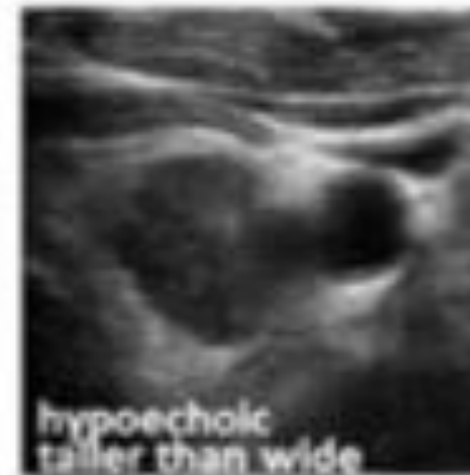
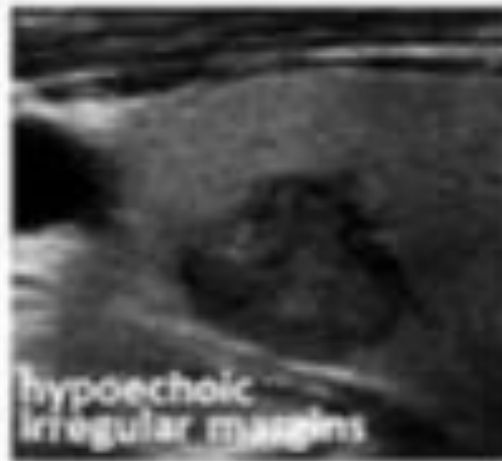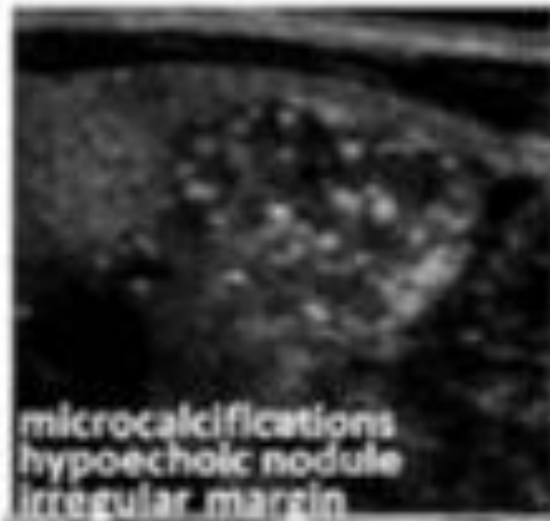Reference: 2015 American Thyroid Association Management Guidelines for Adult Patients with Thyroid Nodules and Differentiated Thyroid Cancer. BR Haugen, EK Alexander et. Al. Thyroid. Volume 26, Number 1, 2016.



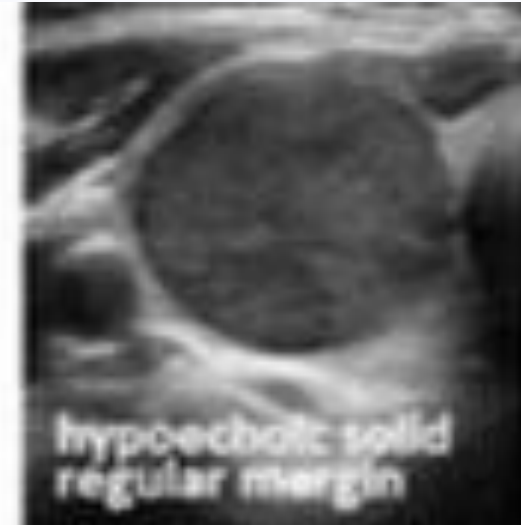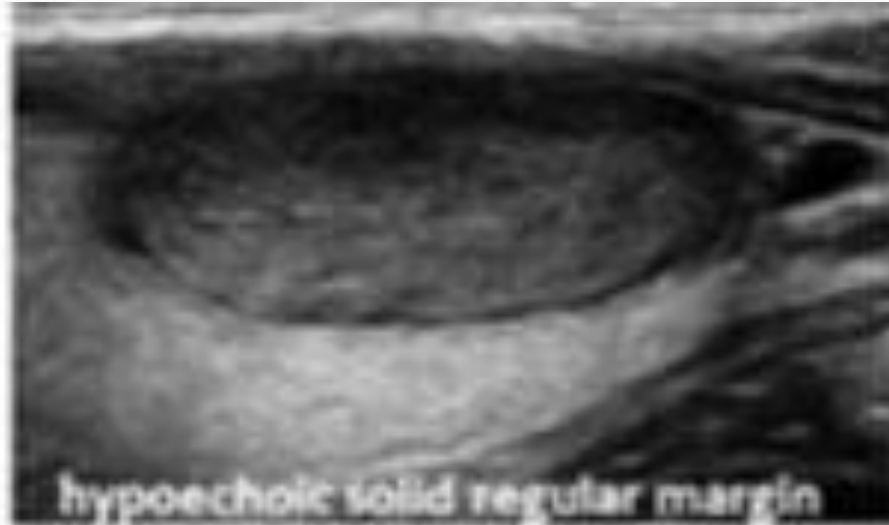


Reference: 2015 American Thyroid Association Management Guidelines for Adult Patients with Thyroid Nodules and Differentiated Thyroid Cancer. BR Haugen, EK Alexander et. Al. Thyroid. Volume 26, Number 1, 2016

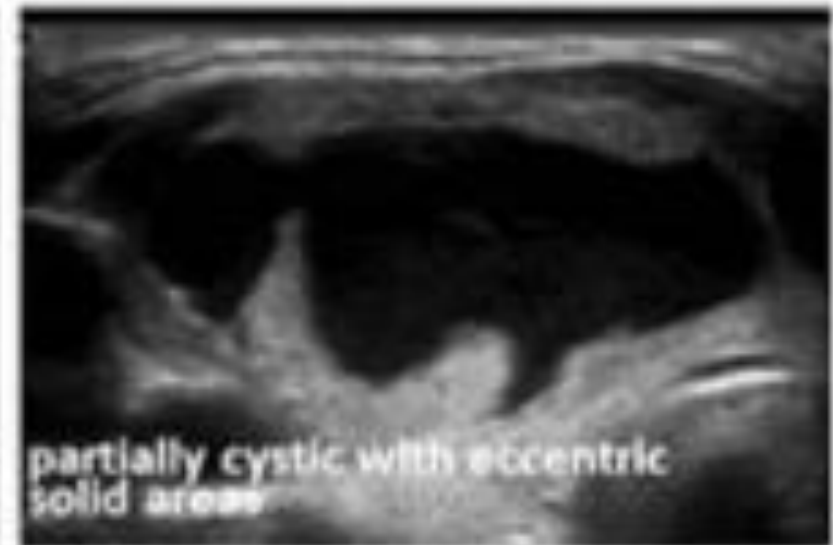
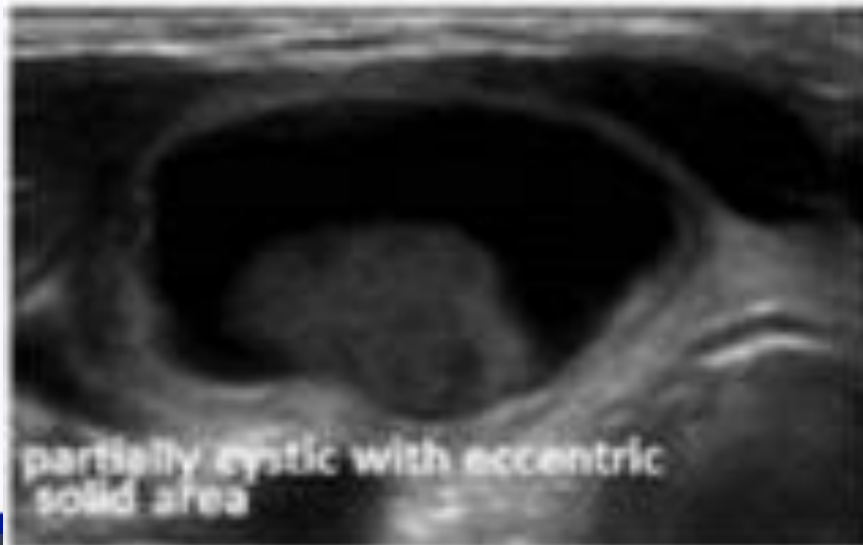
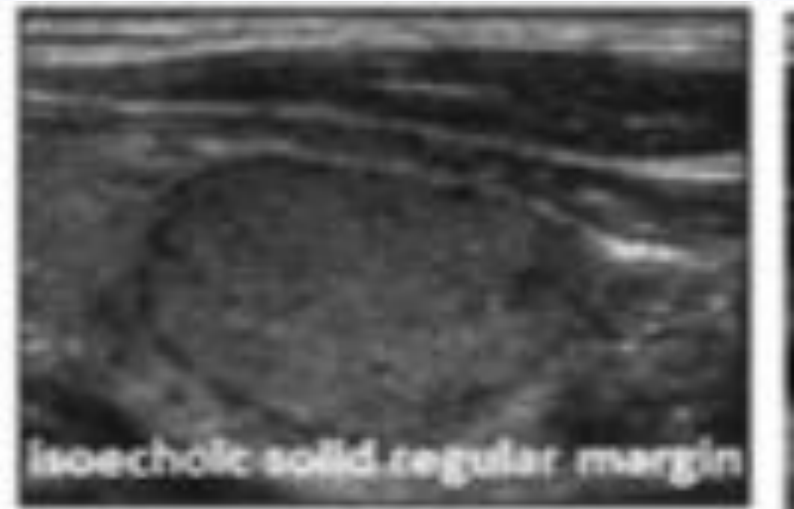
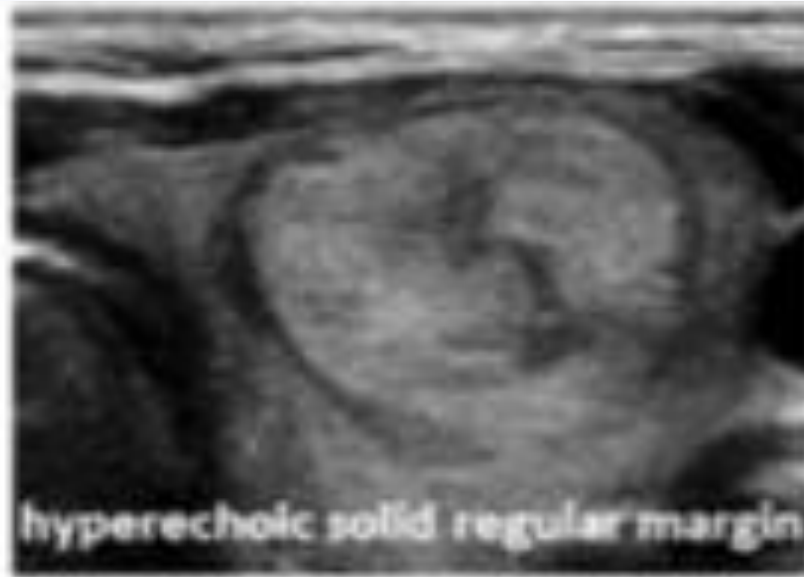High
Suspicion
>70-90%



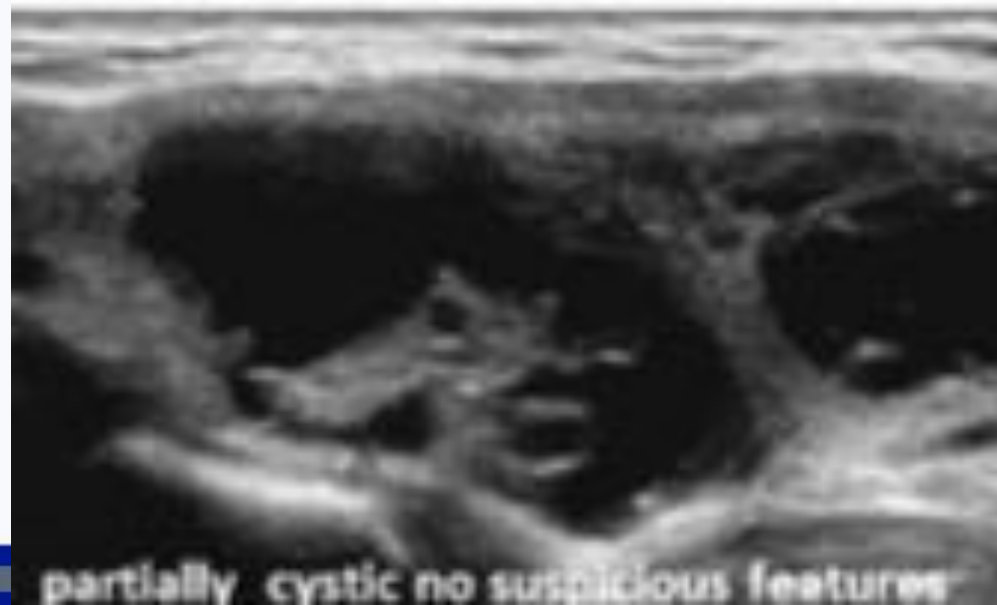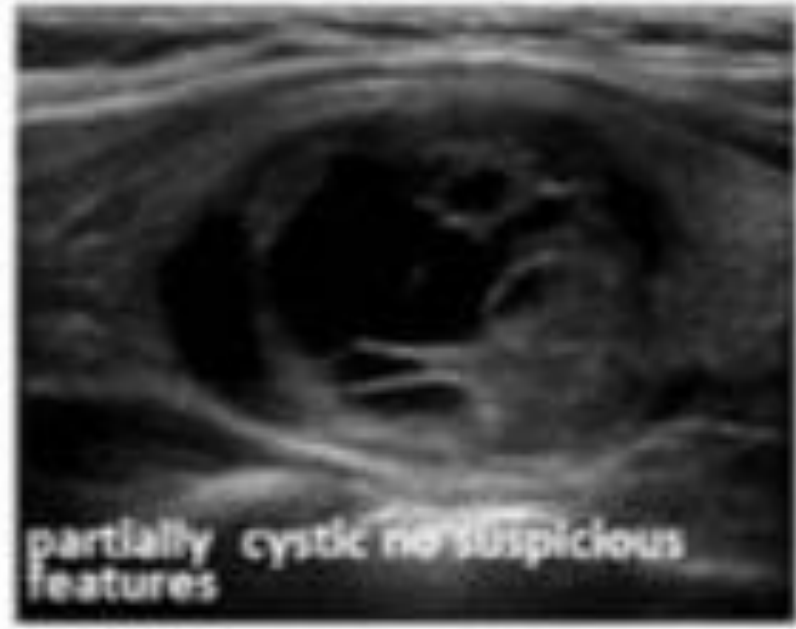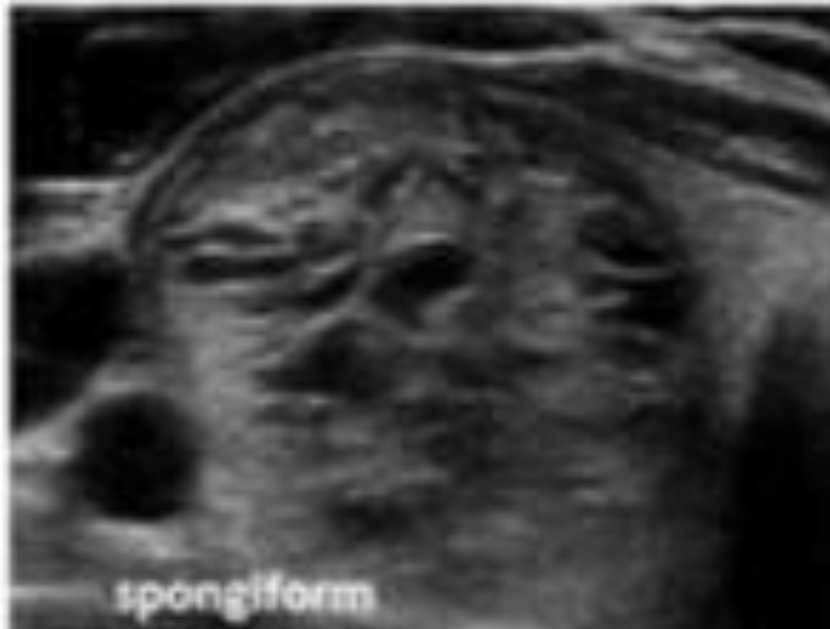**Intermediate
Suspicion
10-20%**



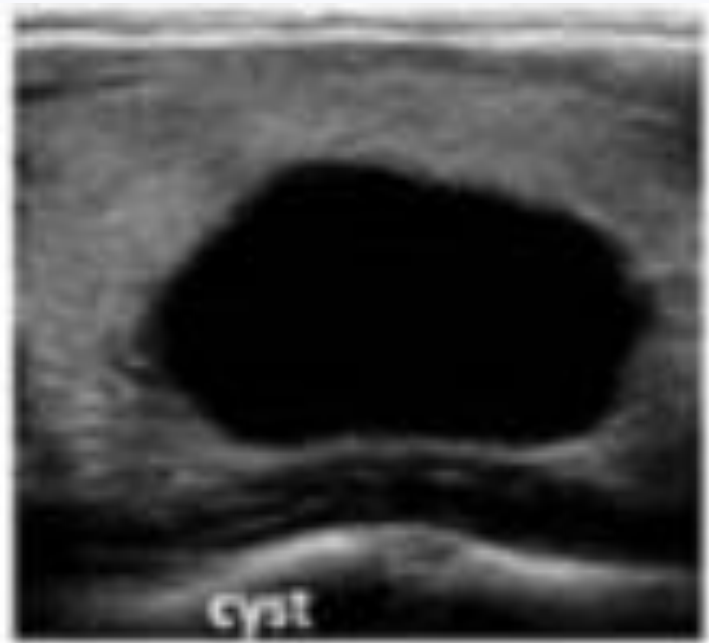
Low
Suspicion
5-10%



Very low
Suspicion
<3%



Benign
<1%



FF Thyroid ultrasound findings

R thyroid lobe

- Measures 8.54x3.33x2.37cm
- Multiple well-defined solid foci are seen, measuring as follows:
 - Upper pole: 1.25x0.95cm, 0.88x0.83x0.69cm, 0.78x0.73x0.57cm
 - Mid segment: 0.54x0.58x0.5cm, 3.9x2.95x2.24cm
 - Lower pole: 1.9x1.82x1.14cm, 0.94x1.04x0.56cm

FF Thyroid ultrasound findings

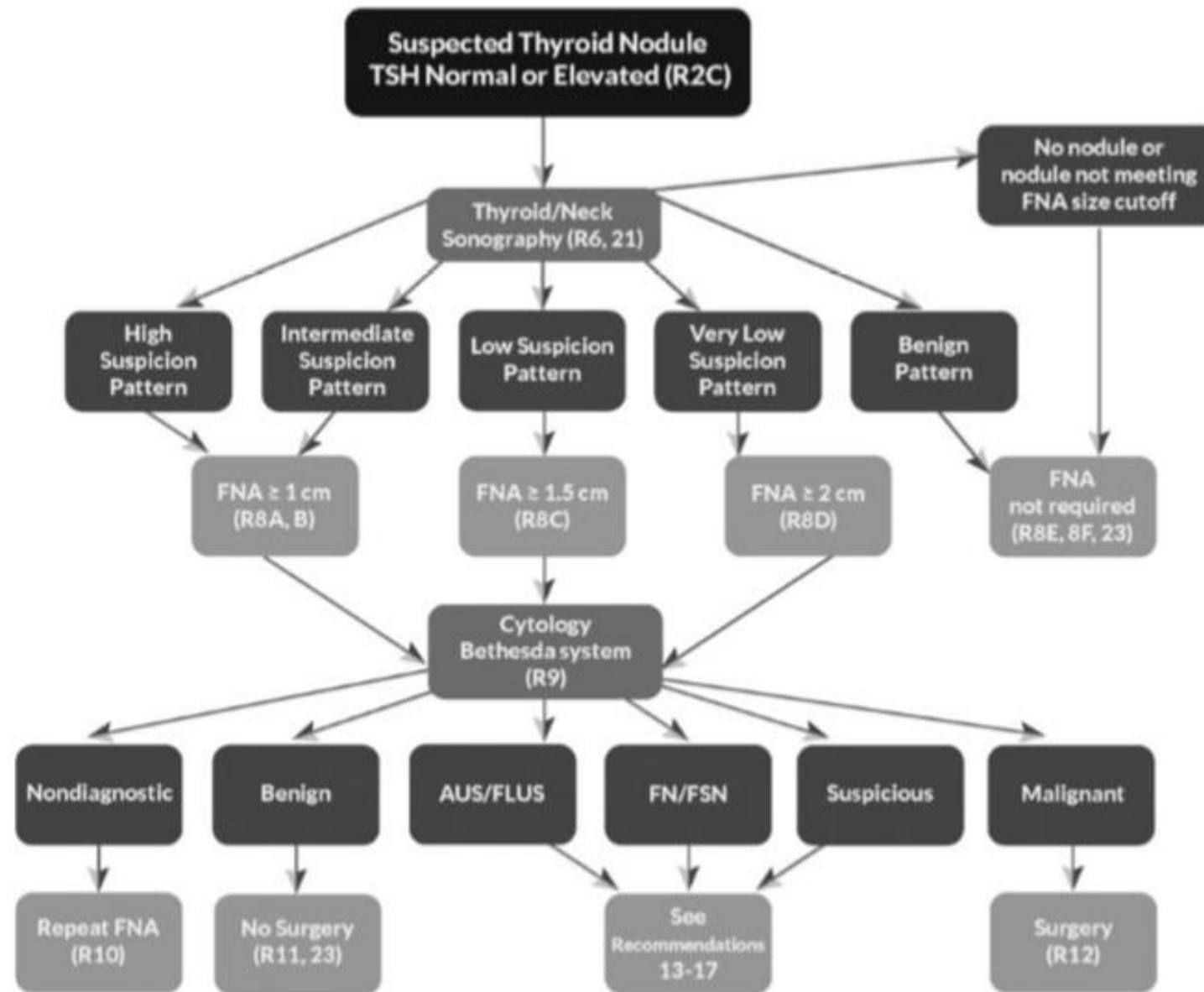
L Thyroid lobe

- Measures 13.69x8.7x5.05cm
- Solid masses noted:
 - Upper pole: 5.99x5.86x4.03cm
 - Mid segment: 6.93x6.49x3.98cm
 - Lower pole: 6.27x6.3x4.73cm
- No significant intralesional vascular flow noted within these masses

Isthmus measures 0.63cm and is thickened

FF Thyroid ultrasound findings

Results are suggestive of Low suspicion pattern



Reference: 2015 American Thyroid Association Management Guidelines for Adult Patients with Thyroid Nodules and Differentiated Thyroid Cancer. BR Haugen, EK Alexander et. Al. Thyroid. Volume 26, Number 1, 2016

Bethesda System for reporting Thyroid Cytopathology

<i>Diagnostic category</i>	<i>Risk of malignancy if NIFTP ≠ CA (%)</i>	<i>Risk of malignancy if NIFTP = CA (%)</i>	<i>Usual management^a</i>
Nondiagnostic or unsatisfactory	5–10	5–10	Repeat FNA with ultrasound guidance
Benign	0–3	0–3	Clinical and sonographic follow-up
Atypia of undetermined significance or follicular lesion of undetermined significance	6–18	~10–30	Repeat FNA, molecular testing, or lobectomy
Follicular neoplasm or suspicious for a follicular neoplasm	10–40	25–40	Molecular testing, lobectomy
Suspicious for malignancy	45–60	50–75	Near-total thyroidectomy or lobectomy ^{b,c}
Malignant	94–96	97–99	Near-total thyroidectomy or lobectomy ^c

Reference: The 2017 Bethesda System for Reporting Thyroid Cytopathology. ES Cibas, SZ Ali. Thyroid/Journal of the American Society of Cytopathology, Volume 27, Number 11, 2017.

I: Nondiagnostic or unsatisfactory

- Inadequate samples
- Includes those with obscuring blood, poor cel'l preservation, insufficient sample of follicular cells
- Only cyst contents

- Recommendation: Repeat FNA with ultrasound guidance
 - If persistent, excision is considered

II: Benign

- Abundant colloid usually
- Very low false-negative rate

- Recommendation: Clinical and sonographic follow-up

III: Atypia of undetermined significance

- Detection of risk of malignancy is challenging
- Subclassification of atypia:
 - Cytologic
 - Architectural
 - Cytologic and architectural
 - Hurthle cell
 - Atypia, not otherwise specified
- A category of last resort
- Recommendation: Repeat FNA, molecular testing or lobectomy

IV: Follicular neoplasm or suspicious for a follicular neoplasm

- Most are hyperplastic proliferations of follicular cells, commonly of multinodular goiter
- “Follicular-patterned cases with mild nuclear changes”, but without true papillae and intranuclear pseudoinclusions
- Recommendation: Molecular testing, lobectomy

V: Suspicious for malignancy

- Raise the possibility of Follicular variant Papillary Thyroid CA or Noninvasive follicular thyroid neoplasm with papillary-like nuclear features
- Guides clinical team towards direction of lobectomy if lesion is confined to just one side
- Recommendation: Near-total thyroidectomy or lobectomy

VI: Malignant

- Conclusive
- Descriptive comments that follow are used for subclassification
- Limited to those with “classical” features of malignancy

- Recommendation: Near-total thyroidectomy or lobectomy

FF – FNAB results

- Cat II: Benign
- Consistent with colloid nodule with cystic degeneration



PLAN



DEPARTMENT OF OTORHINOLARYNGOLOGY
PHILIPPINE GENERAL HOSPITAL

Total Thyroidectomy

World J Surg (2010) 34:1203–1213

DOI 10.1007/s00268-010-0491-7

World Journal
of Surgery

Five-year Follow-up of a Randomized Clinical Trial of Total Thyroidectomy versus Dunhill Operation versus Bilateral Subtotal Thyroidectomy for Multinodular Nontoxic Goiter

Marcin Barczyński · Aleksander Konturek ·
Alicja Hubalewska-Dydejczyk · Filip Gołkowski ·
Stanisław Cichoń · Wojciech Nowak



DEPARTMENT OF OTORHINOLARYNGOLOGY
PHILIPPINE GENERAL HOSPITAL

Background

- Extent of thyroid resection in bilateral multinodular nontoxic goiter (MNG) remains controversial in other countries
- Low-volume surgeons avoid performing total thyroidectomy due to possible complications
 - Permanent recurrent laryngeal nerve (RLN) palsy
 - Permanent hypothyroidism
- However, there is increasing acceptance for total thyroidectomy in bilateral MNG
 - Eradicates disease process
 - Lowers recurrence rate
 - Avoid substantial risk for surgery
 - Minimal risk of morbidity

Background

- To evaluate results of various resection modes (Total Thyroidectomy, Dunhill Procedure, Bilateral Subtotal Thyroidectomy) with special emphasis on the recurrence rate and morbidity rate in a 5 year follow up

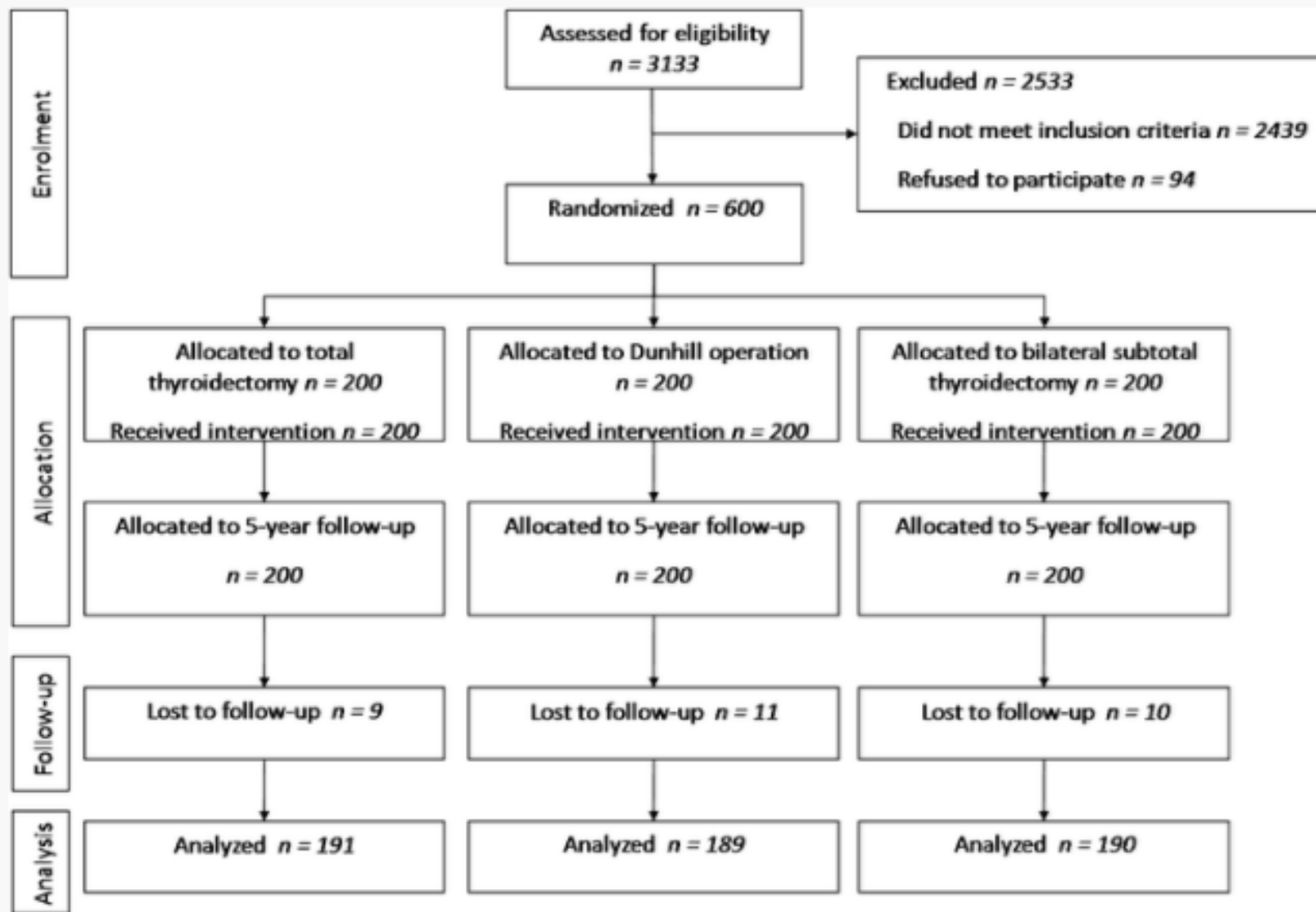


Fig. 1

Flow diagram of the study showing the number of patients randomized originally and available for follow-up at 5 years

Surgical Technique

- All operations were performed by 3 same experienced endocrine surgeons
 - ~ 1/3 of the operation in each study group was done by each surgeon
- Total Thyroidectomy
 - Extracapsular Thyroidectomy
- Dunhill Operation
 - Unilateral extracapsular total thyroidectomy and contralateral subtotal thyroid lobe resection (~2g normal thyroid tissue)
- Bilateral Subtotal Thyroidectomy
 - Bilateral subtotal thyroidectomy (~2g of normal thyroid tissue, bilateral)

Preoperative Evaluation

- High resolution doppler ultrasound of the neck was done by a single endocrine surgeon experienced in thyroid imaging
- FNA was performed in all patients prior to the study
- Serum FT3, FT4, TSH and TPO

Postoperative Follow-up

- Ultrasonographic, cytologic and biochemical follow-up 60 months postop
- Indirect laryngoscopy
- Serum calcium

Results

Table 1

Demographic characteristics of 570 patients who completed the 5-year follow-up

	TT (n = 191)	DO (n = 189)	BST (n = 190)
Sex ratio (M:F) ^a	17:174	20:169	16:174
Mean age, years ^b	46.51 ± 14.11	47.22 ± 15.61	48.23 ± 15.44
Preoperative TSH, mIU/l ^b	1.90 ± 0.89	1.82 ± 0.81	1.78 ± 0.92
Preoperative thyroid volume (assessed by ultrasound), ml	76.6 ± 38.9	77.8 ± 39.5	78.9 ± 40.1

TT total thyroidectomy; *DO* Dunhill operation; *BST* bilateral subtotal thyroidectomy; TSH thyroid stimulating hormone

^a χ^2 -test

^b*t*-test; statistically nonsignificant differences for all values

Results

Table 3

Final pathology and need for completion thyroidectomy for 570 patients who completed the 5-year follow-up

	TT (n = 191)	DO (n = 189)	BST (n = 190)
Benign multinodular goiter, n (%)	173 (90.58)	174 (92.06)	174 (91.58)
Incidental thyroid cancer, n (%) ^a			
Total	18 (9.42)	15 (7.94)	16 (8.42)
Papillary	15 (7.85)	13 (6.88)	13 (6.88)
pT1aNoMo	12 (6.28)	11 (5.82)	11 (5.82)
pT1mNoMo	3 (1.57)	2 (1.05)	2 (1.05)
Follicular, pT2NoMo	2 (1.05)	1 (0.53) ^b	2 (1.05)
Hürthle cell, pT2NoMo	1 (0.53)	1 (0.53)	1 (0.53)
Need for completion thyroidectomy, n (%)			
Total	1 (0.52) [†]	3 (1.57)	7 (3.68) [†]
For cancer	0 (0) [‡]	2 (1.05)	5 (2.63) [‡]
For goiter recurrence	1 (0.53)	1 (0.53)	2 (1.05)

Differences were statistically nonsignificant, unless otherwise indicated (χ^2 -test: [†] $p = 0.03$; [‡] $p = 0.01$)

^aStaging according to International Union against Cancer (UICC) TNM classification (2002)

^bA case of minimally invasive follicular thyroid cancer

Table 2

Recurrence rate, timing of nodular goiter recurrence, and levothyroxine substitution data among 570 patients who completed the 5-year follow-up

Follow-up time, months	Goiter recurrence, n (%)		
	TT (n = 191)	DO (n = 189)	BST (n = 190)
0–12	0 (0)	0 (0)	0 (0)
24	0 (0)	1 (0.52)	2 (1.05)
36	1 (0.52)	2 (1.05)	3 (1.57)
48	0 (0)	3 (1.57)	7 (3.68)
60	0 (0)	3 (1.57)	10 (5.26)
Total recurrence	1 (0.52) ^{†‡}	9 (4.71) ^{†*}	22 (11.58) ^{‡*}
Mean levothyroxine dose, μg^{a}	100.59 \pm 14.53 ^{**#}	96.29 \pm 17.78 ^{**§}	77.16 \pm 24.30 ^{#§}

χ^2 test: [†] $p = 0.01$; [‡] $p < 0.001$; ^{*} $p = 0.02$; ^{**} $p = 0.04$; ^{#§} $p < 0.001$

^aMean cumulated levothyroxine substitutive dose during 5-year follow-up

Results

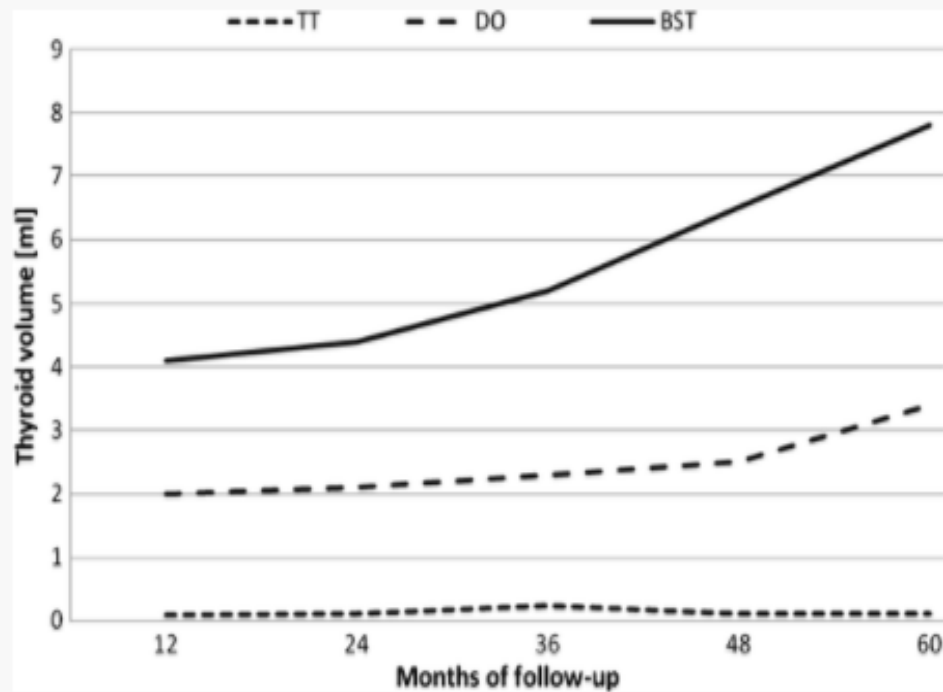


Fig. 3
Five-year follow-up data of mean volume of the remnant thyroid tissue (assessed by ultrasonography at yearly intervals). The remnant thyroid volume in the BST group was significantly larger after 60 months of follow-up (paired t -test: $p < 0.001$), whereas nonsignificant differences were observed in the DO group

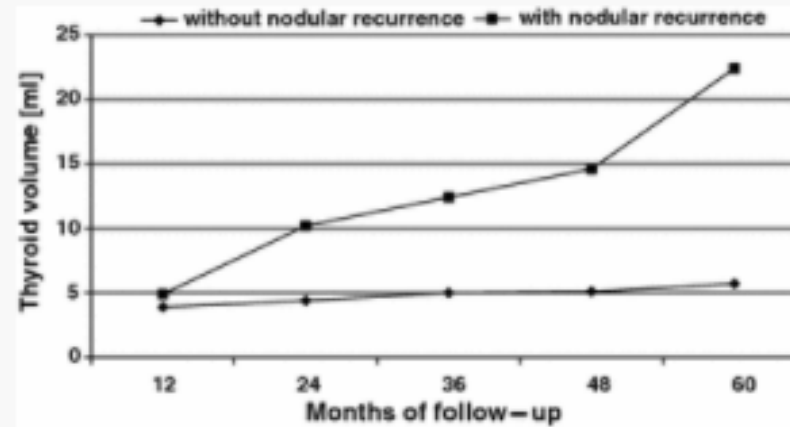


Fig. 4
Five-year follow-up data of mean volume of the remnant thyroid tissue in the BST group (assessed by ultrasonography at yearly intervals). The remnant thyroid volume in 22 patients with recurrence versus 168 patients without recurrence was significantly larger from 24 to 60 months of follow-up (paired t -test; $p < 0.001$)

Results

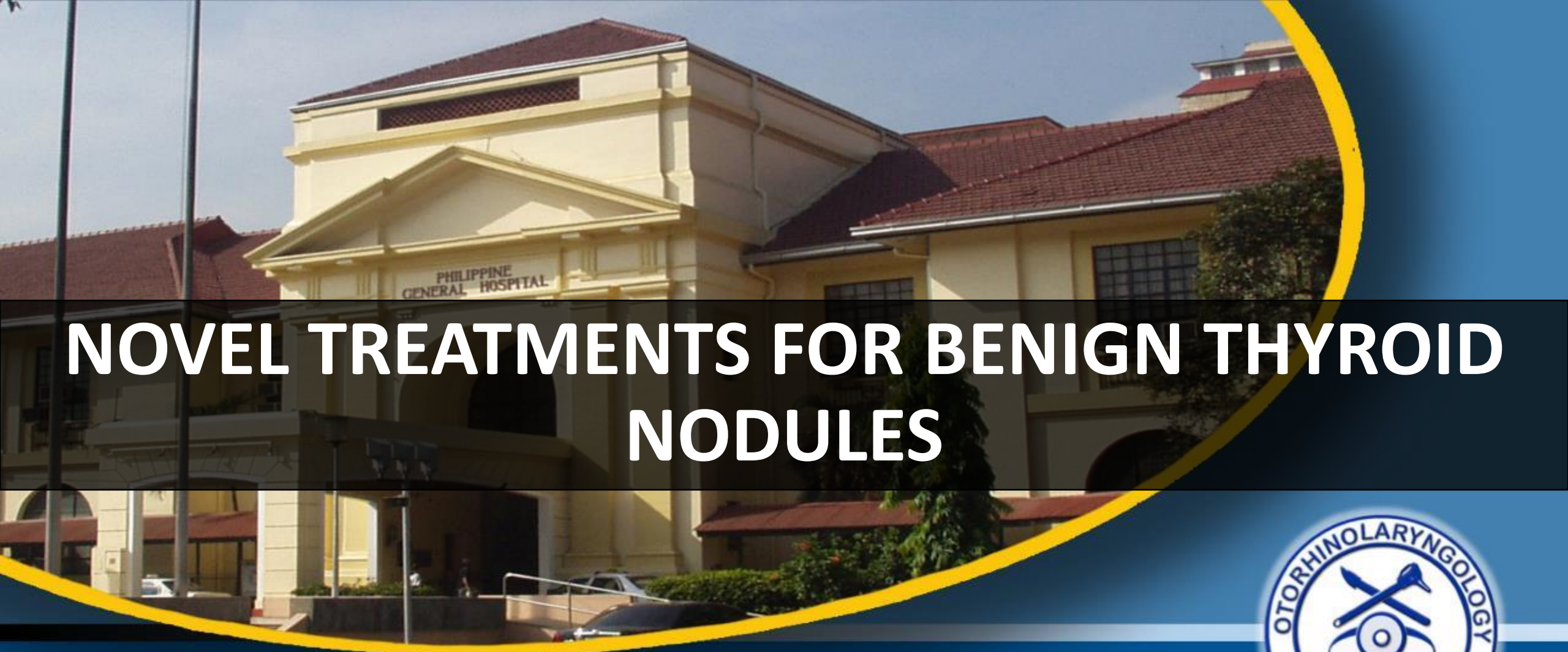Table 4

Operative time and complications after thyroidectomy among 570 patients who completed the 5-year follow-up

	TT (n = 191)	DO (n = 189)	BST (n = 190)
Operating time, min	69.12 ± 14.23	68.31 ± 14.18	67.12 ± 13.94
Hypoparathyroidism, n (%)			
Total	22 (11.52) ^{†‡}	8 (4.23) [‡]	4 (2.10) [†]
Transient	21 (10.99) ^{†‡}	8 (4.23) [‡]	4 (2.10) [†]
Permanent	1 (0.53)	0 (0)	0 (0)
Recurrent laryngeal nerve injury, n (%) ^a			
Total	25 (6.54) [*]	19 (5.02)	10 (2.63) [*]
Temporary	21 (5.49) [§]	16 (4.23)	8 (2.10) [§]
Permanent	4 (1.05)	3 (0.79)	2 (0.53)
Hemorrhage, n (%)	0 (0)	1 (0.53)	2 (1.05)

Conclusion

- Total Thyroidectomy can be regarded as the procedure of choice in patients with Multinodular Goiter with significant lower incidence of goiter recurrence and less frequent need for completion thyroidectomy.
- This however confers a significantly higher risk of postoperative transient but not permanent hypoparathyroidism and recurrent laryngeal nerve paresis.



NOVEL TREATMENTS FOR BENIGN THYROID NODULES



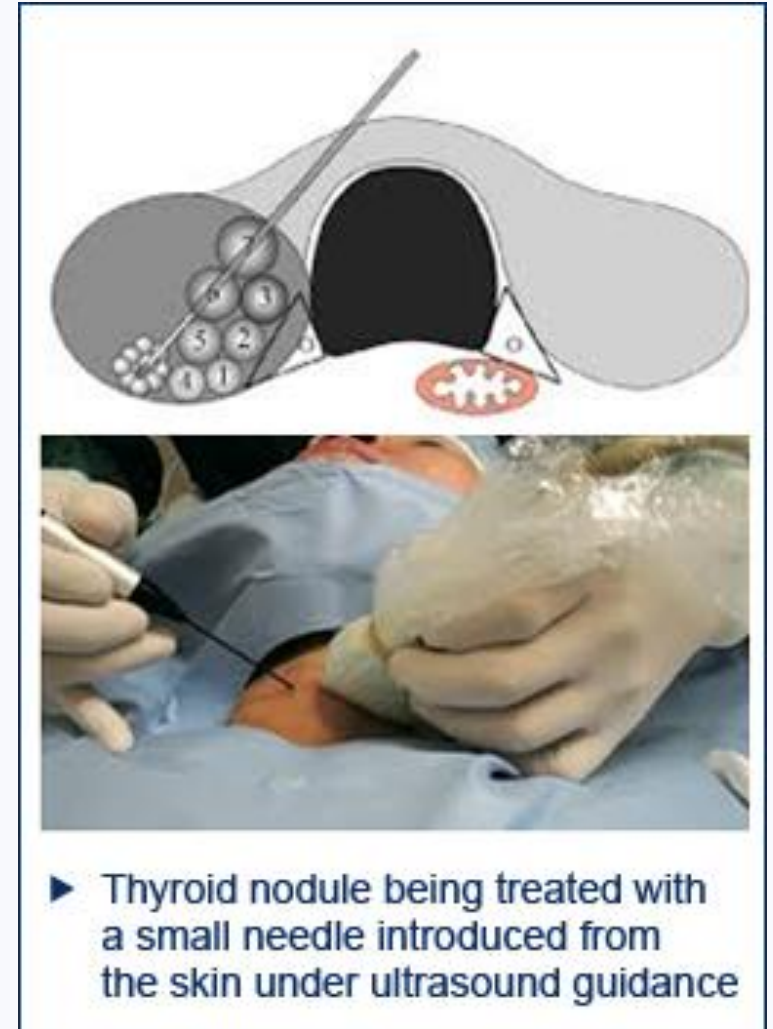
DEPARTMENT OF OTORHINOLARYNGOLOGY
PHILIPPINE GENERAL HOSPITAL

Introduction

- A significant proportion of the population have thyroid nodules (20-76%)
- Majority are benign (Cat II)
- ATA 2015 guidelines for benign thyroid nodules
 - TSH suppression – NO LONGER RECOMMENDED (strong recommendation, high quality evidence)
 - Surgery (weak recommendation, low-quality evidence)
 - If nodules are large (>4 cm)
 - Compressive symptoms
 - Clinical suspicion of malignancy
 - Observation (strong recommendation, low-quality evidence)
 - Percutaneous ethanol injection for cystic nodules (weak recommendation, low-quality evidence)

Percutaneous treatments

- Image-guided ablation of thyroid nodules
- Ethanol
 - Disadvantages: hoarseness (ethanol leakage)
- Laser ablation
 - Disadvantages: transient hyperthyroidism, hematoma, hoarseness
- Radiofrequency
 - Applies thermal energy to induce tissue necrosis of thyroid nodules
 - Disadvantages: may induce autoimmune thyroid disease, skin burns, adhesion formation



[Medicine \(Baltimore\)](#). 2016 Aug; 95(34): e4659.

PMCID: PMC5400335

Published online 2016 Aug 26. doi: [10.1097/MD.00000000000004659](https://doi.org/10.1097/MD.00000000000004659)

Radiofrequency ablation for treatment of benign thyroid nodules

A PRISMA-compliant systematic review and meta-analysis of outcomes

[Fen Chen](#), PhD,^a [Guo Tian](#), MD,^b [Dexing Kong](#), PhD,^c [Liyun Zhong](#), MD,^d and [Tian'an Jiang](#), PhD^{d,*}

Monitoring Editor: Eleonore Fröhlich.



Methodology

- Meta-analysis of all published literature until January 27, 2016
- Inclusion criteria
 - Original research
 - Retrospective or prospective studies
 - Examined any or all of the following results
 - Nodule volume
 - Largest diameter
 - Symptom score
 - Cosmetic score
 - TSH, fT3, fT4
 - vascularity

Results

- 20 studies
- 1090 patients

- Age: 13-89 years old
- Sex: 78.6% female

Results

Table 3

Subgroup analysis of the outcomes before and after RFA.

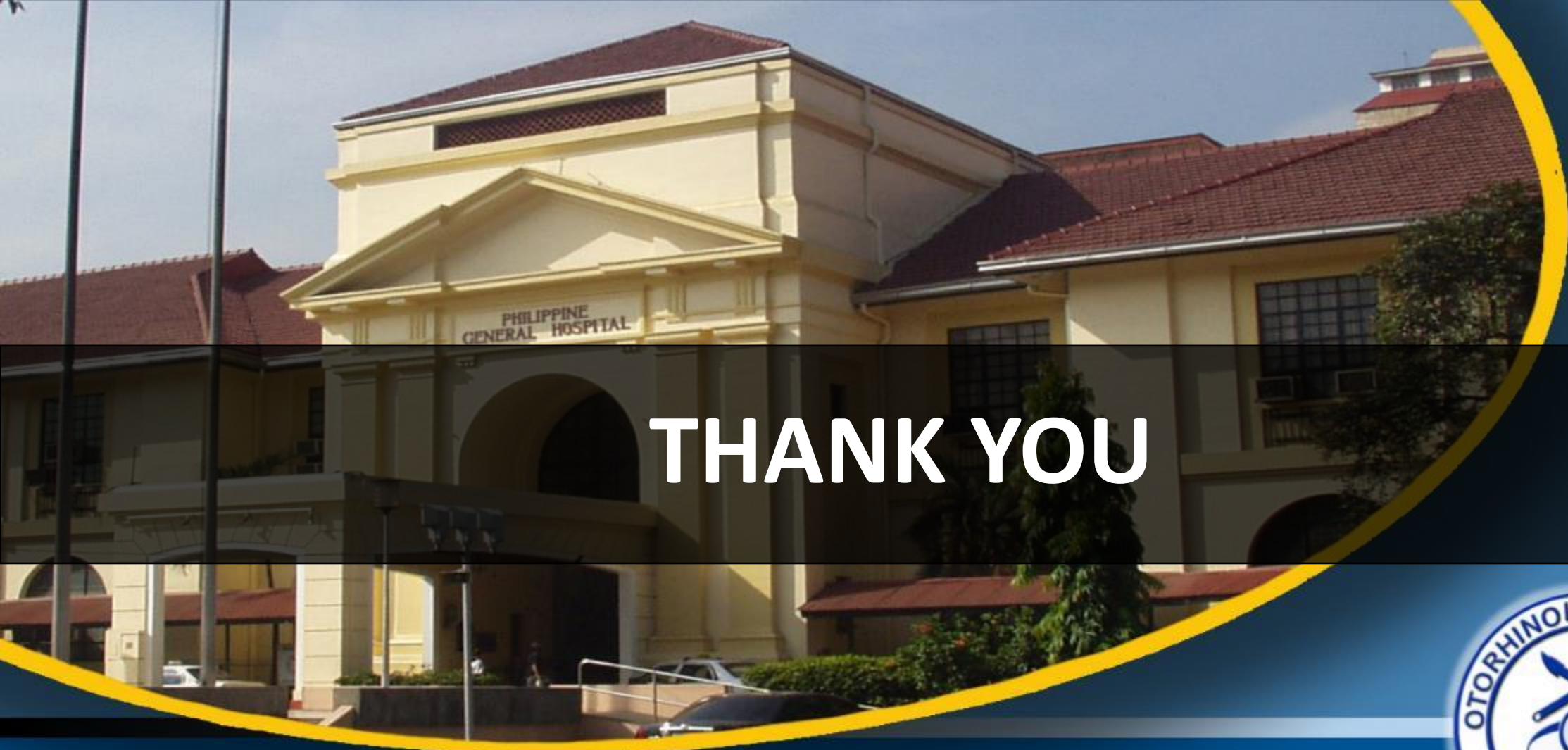Subgroup	Number of studies	SMD (95%CI)	Z score	P*
Nodule volume				
1 mo	9	0.83 (0.47–1.19)	4.54	<0.001
3 mo	7	1.31 (0.76–1.85)	4.67	<0.001
6 mo	15	1.25 (0.90–1.59)	7.03	<0.001
12 mo	6	4.16 (2.25–6.07)	4.27	<0.001
Last month	20	1.73 (1.27–2.18)	7.43	<0.001
Cold nodule	10	2.02 (1.10–2.93)	4.32	<0.001
Hot nodule	5	2.05 (0.88–3.21)	3.44	0.001
Largest diameter	7	1.43 (0.97–1.90)	6.06	<0.001
Symptom score	16	3.11 (2.28–3.94)	7.32	<0.001
Cosmetic score	12	2.77 (2.18–3.36)	9.17	<0.001
TSH	8	-0.44 (-0.86–0.02)	2.03	0.042
T3	4	0.33 (0.06–0.60)	2.43	0.015
fT4	7	0.46 (-0.29–1.22)	1.20	0.230
Vascularity	2	1.78 (0.31–3.25)	2.38	0.017

Discussion

- RF ablation also affects thyroid vascularity which leads to reduced production of T3 and T4 and accelerated secretion of TSH
- Symptoms and cosmesis also improved

Limitations

- Heterogenous inclusion criteria
- Limited sample size
- Selection bias – most studies came from Korea, Italy



PHILIPPINE
GENERAL HOSPITAL

THANK YOU



DEPARTMENT OF OTORHINOLARYNGOLOGY
PHILIPPINE GENERAL HOSPITAL