

Cosmetics through the ages

1. “The story of cosmetics and perfumery forms a continuous narrative throughout the history of man, developing as he developed. The origins are associated with fighting, hunting, religion and superstition; later with medicine; then, as knowledge increased, becoming dissociated from medicine and allied to pharmacy.” (Butler, H., 2000)
2. Cosmetic products use today were not all created in recent history. Some of them have long and storied history that reaches the very beginning of the modern human civilization.
3. Although for the purpose of beautifying, perfuming, cleansing, or rituals have existed since the origin of civilization, only in the 20th century has great progress been made in the diversification of products and functions and in the safety and protection of the consumer.

Cutaneous Formulation Issues

Cutaneous Formulation Issues

- When formulating for the skin, consider the anatomic area involved individually to achieve optimal product functioning.
- “Failure to do so leads to development of a product that works everywhere and nowhere.” (Draelos, Z.D., 2006)

Cutaneous Formulation Issues

- To understand formulation needs of each body area, several basic concepts must be considered.
 1. The anatomy and physiology of the body site must be identified;
 2. The dermatologic diseases that may afflict the given skin area. **Good skin care products should supplement prescription medications when disease is present, but also maintain the health of the skin and prevent disease recurrence once resolution of the dermatologic problem has occurred.**
 3. The hygiene needs of the skin should be considered;
 4. Thought should be given what constitutes skin health in the area and what skin care needs should be met to allow maintenance of this health.

Site Specific Cutaneous Needs

1. The face
2. The eyelids and lips;
3. The hands and feet
4. Nails and cuticles
5. The scalp
6. The Neck and the underarms
7. The male and female genitalia

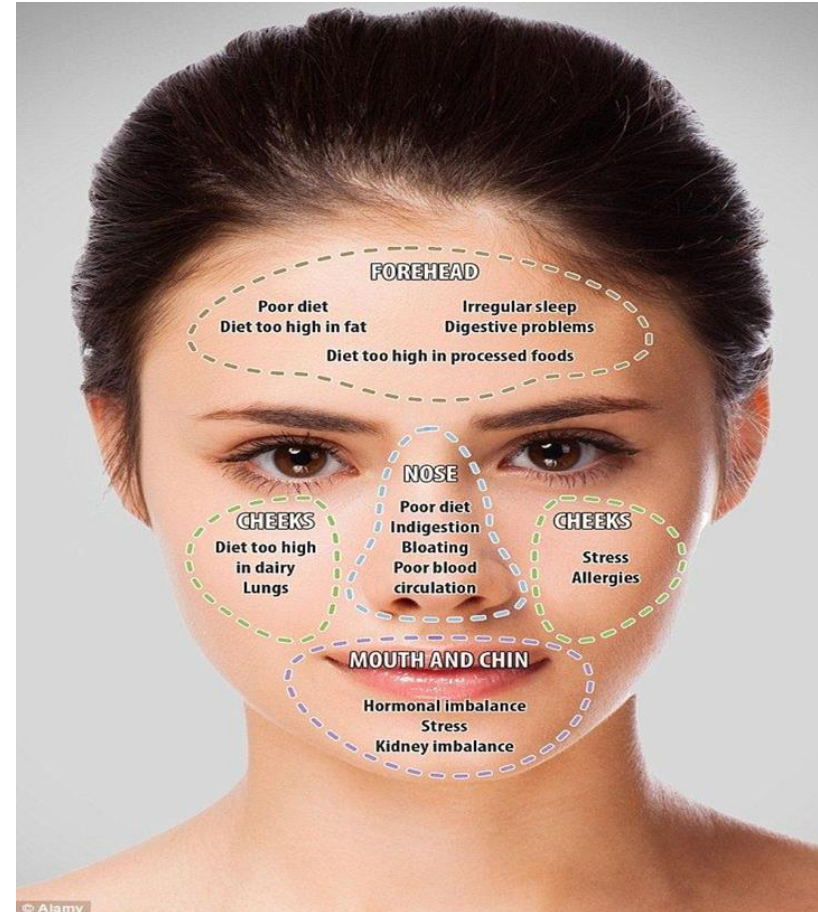
The Face

- The face begins at the anterior hairline, stops at the ears, and is bounded by the lateral jawline and chin.
- It is the most complex and challenging area of the body for the formulator, yet more products are designed for facial use than any other.
- the face is the purveyor of our image, our personality, our health, and our age. It identifies who we are, how we are, where we are, and sometimes what we hope to be.



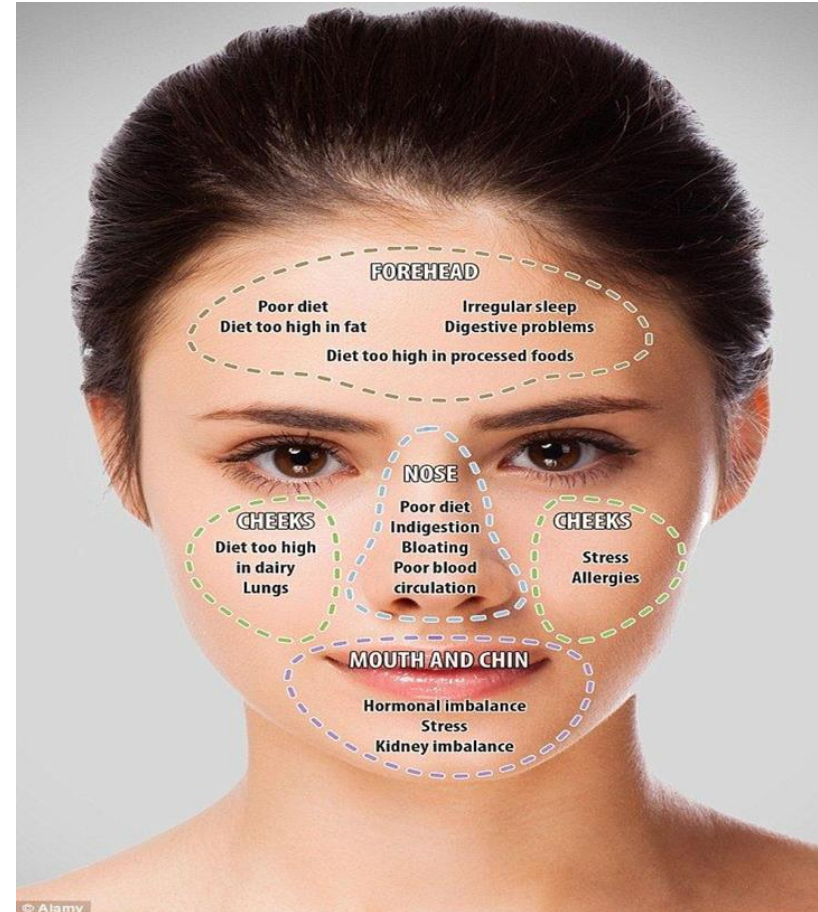
The Face

- From a dermatologic standpoint, the face possesses unique medical attributes.
- It contains all of the glandular structures of the body, including hair, and is characterized by dry skin and transitional skin. The transitional skin is found around the eyes, nose, and mouth. It is also frequently afflicted by a variety of skin diseases that complicate product development.



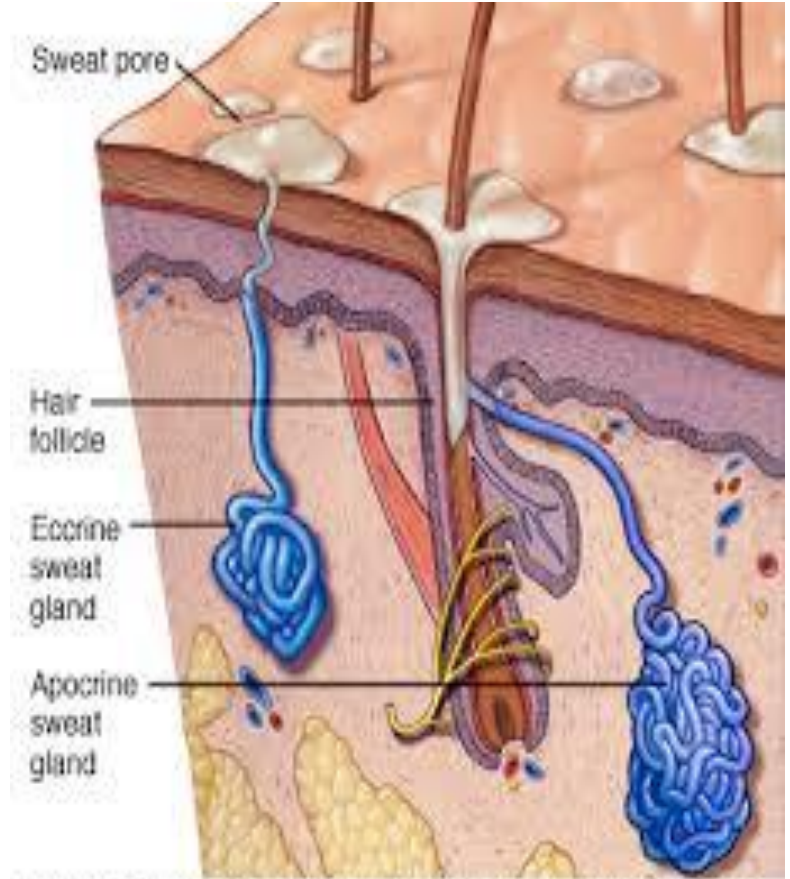
The Face

- The facial skin is the thinnest on the body, except for that around the eyelids. This means that the skin is easy to injure, but also readily healed.
- On the other hand, the facial skin is some of the least forgiving when it comes to irritation and allergy



Anatomy and Physiology

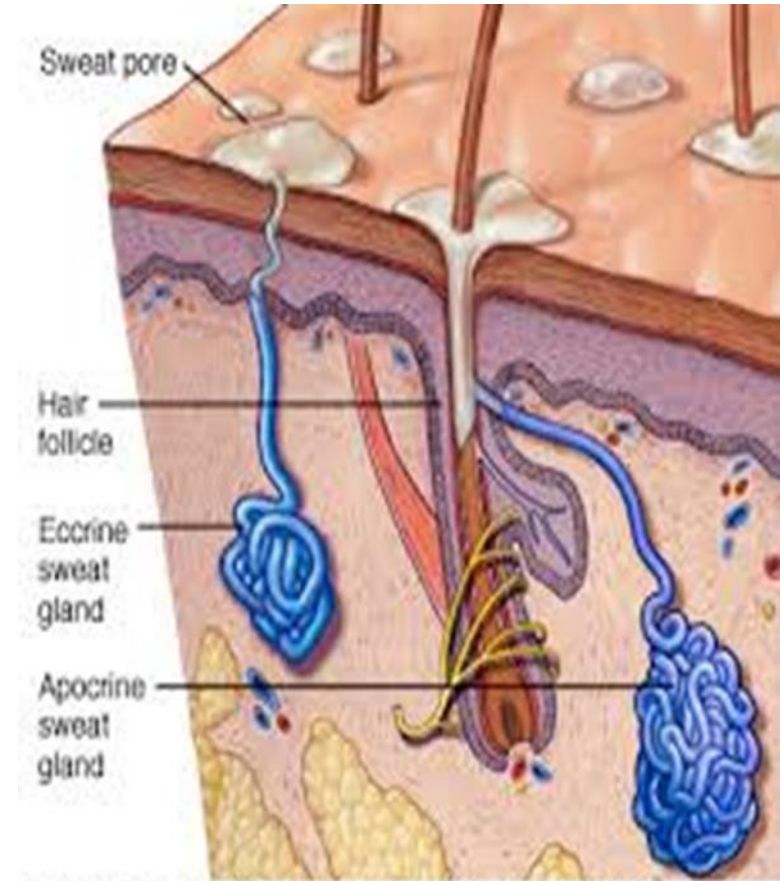
- The facial skin also contains two types of sweat glands, known as eccrine and apocrine glands. Eccrine glands are the sweat glands that produce a sterile watery liquid associated with the maintenance of body temperature. It is the evaporation of the sweat from the skin surface that allows excess heat to be rapidly removed from the body



© MAYO FOUNDATION FOR MEDICAL EDUCATION AND RESEARCH. ALL RIGHTS RESERVED.

Anatomy and Physiology

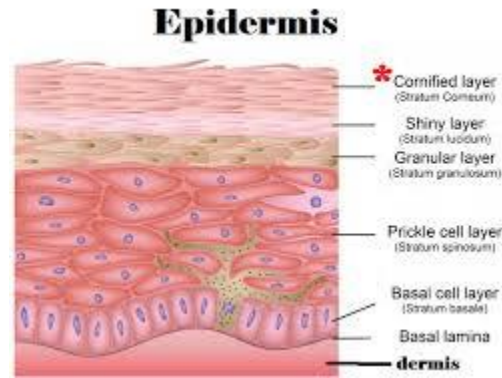
- The other type of sweat gland, known as an apocrine gland, produces a scented sweat that is unique to each individual.
- Eccrine glands, and Apocrine glands. The face possesses a larger variety of these structures than any other skin on the body, which makes it unique.



Anatomy and Physiology

- The epidermis is the outer layer of skin, which is covered by a thin layer of nonliving skin cells, known as the stratum corneum.
- The **stratum corneum** is the layer of skin with which all skin care products interact. It is this structure that is impacted by the majority of formulations concocted by the cosmetic chemist.
- Beneath the epidermis lies the dermis. The dermis is the collagen-rich, structurally strong layer of skin.
- The dermis actively participates in the immunologic surveillance of the body and produces a scar if injured. For all practical purposes, the cosmetic chemist is not concerned with the dermis as this is the realm of prescription drugs.

Anatomy and Physiology



- The stratum corneum, is the skin barrier, plays integral role in differentiating those substances that must remain outside the body from those that are allowed to enter
- It accomplishes this end by a unique arrangement of dehydrated skin cells, known as corneocytes, interspersed between a combination of oily substances, known as intercellular lipids. The intercellular lipids implicated in epidermal barrier function include sphingolipids, free sterols, and free fatty acids .
- This organization has been likened to a brick wall where the bricks are represented by the nonliving corneocytes and the mortar is represented by the intercellular lipids. Any disruption in this organization, either through removal of the coreneocytes or intercellular lipids, results in a barrier defect that can ultimately result in skin disease

Common Dermatological Skin Conditions

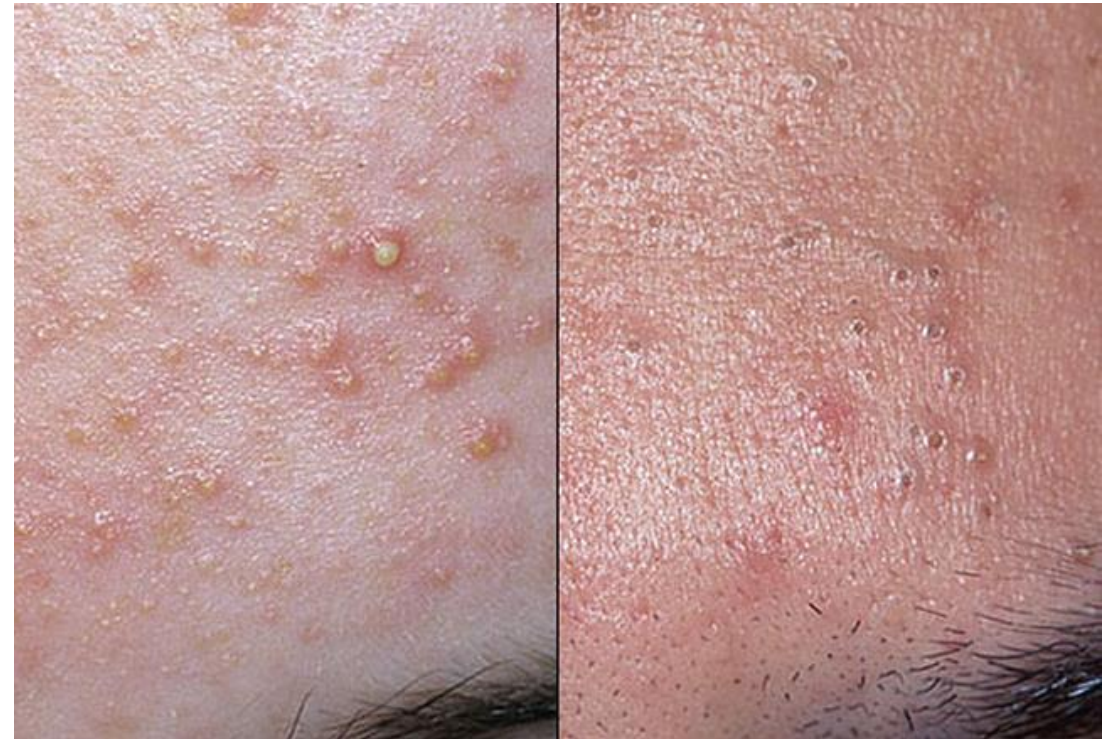- The causes of most facial skin diseases that can be impacted by skin care products are due to barrier defects. The barrier defects are mostly due to removal of the intercellular lipids resulting in excessive water loss from the skin surface, a phenomenon known as **transepidermal water loss**. This loss of water from the skin produces dryness, known as xerosis, with the onset of flaking of the facial skin later accompanied by redness and swelling.
- These physical findings are associated with the subjective findings of tightness, itching, stinging, burning, and pain, in order of increasing skin disease severity. It is the onset of this transepidermal water loss that is necessary to initiate synthesis of intercellular lipids to allow barrier repair

Common Dermatological Disease Conditions

- The skin disease that results from dryness is known as eczema. Eczema is treated by creating an environment suitable for barrier repair to occur. Most dermatologists recommend decreased bathing and use of a mild detergent to prevent further undesirable removal of the intercellular lipids.
- They also recommend the use of oily moisturizers to create an artificial barrier soothing irritated nerve endings, thus preventing itching and pain, and to decrease transepidermal water loss. Moisturizers are used not to hydrate the skin, but rather to minimize further damage while the skin is healing the barrier endogenously

Common Dermatological Disease Conditions

- Acne and seborrheic dermatitis due to skin biofilm abnormalities in the presence of bacteria and fungi.
- Acne due to sebum produced by the sebaceous gland of the facial skin which is food for *Propionibacterium acnes*, and fungal elements, such as *pityrosporum* species
- Dandruff of the face or seborrheic dermatitis



Hygiene Needs

- The hygiene needs of the face are more complex than any body area, except perhaps, the genitalia. This is due to the interplay between the skin, the hair, the sebaceous glands, the eccrine glands, and the transitional skin around the eyes, nose, and mouth.
- The moist skin of the nasal mucosa and the oral mucosa is an environment perfect for bacterial colonization and growth. Bacteria from these sites can easily move onto the facial skin covered with a mixture of sebum and sweat perfect for encouraging bacterial growth and spreading infection. The presence of hair also provides added surface area for bacterial growth to occur, thus the facial skin is a common site of infection.

Hygiene Needs

- Good facial hygiene is a careful balance between maintaining a healthy biofilm

while preserving the integrity of the barrier by leaving the intercellular lipids intact.

- This can be challenging in light of the fact that cleansers cannot accurately differentiate between sebum and intercellular lipids. It is further challenged by the ever changing sebum production of the facial glands, which varies by both age and climate, and the different bacteria with which the body comes in contact. Many dry complected individuals fail to clean the face due to the fear that dryness will result. Ultimately, disease results.
- Thus, facial skin must be kept clean, but not too clean.

Skin Care Needs



- In many cases, barrier damage from meeting the hygiene needs of the skin must be balanced by the use of additional skin care products. Thus, the skin care needs of the face are influenced not only by the unique attributes of the facial skin, but also by the needs created through the use of other skin care products.

What are the skin care needs of the face?

They are the maintenance of skin health and the enhancement of skin beauty.

These are two very different goals. The maintenance of skin health means optimization of the biofilm, which is a careful balance between cleansing and moisturizing. Yet, there are other skin needs. **These include the creation of**

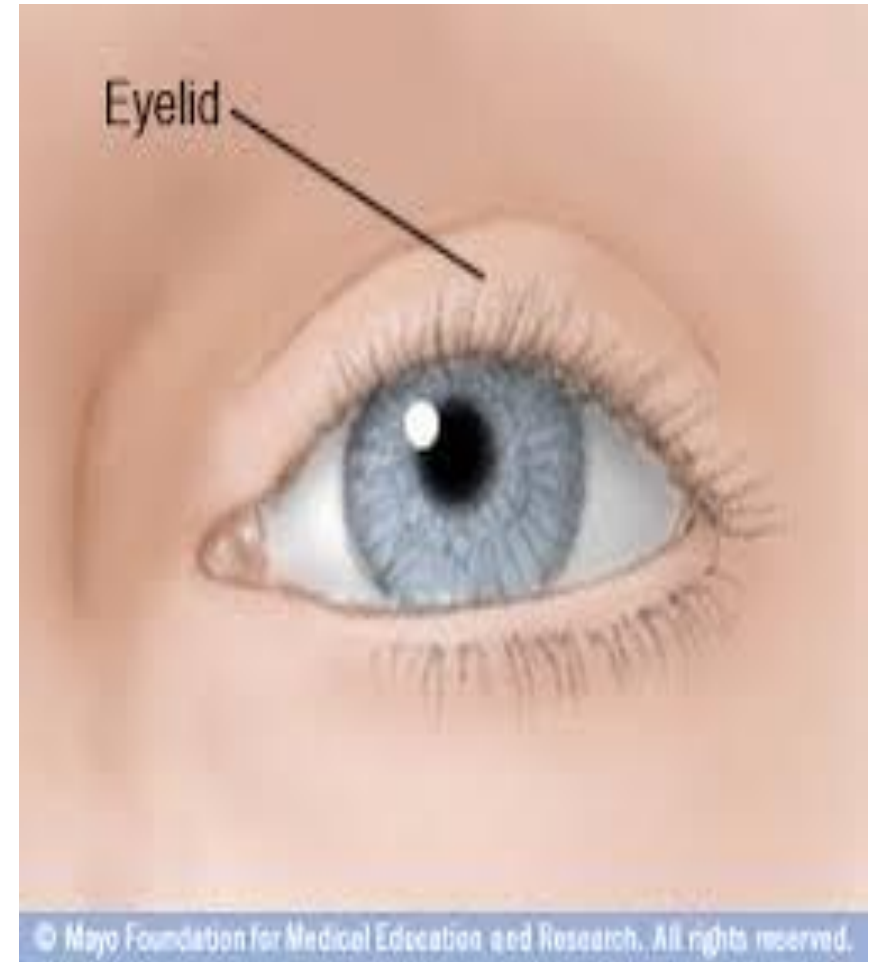
- **an even skin surface and the prevention and reversal of skin damage.**

Skin Care Needs

- The image of healthy facial skin is shiny skin due to abundant light reflection. This light reflection is due to an even surface. Causes of uneven facial skin include scars, facial growths such as moles, skin disease such as acne, and retained dead skin cells from the stratum corneum, known as corneocytes.
- During youth the corneocytes slough easily as the cellular message for cell disadhesion is well transmitted. With advancing age, the cells do not disadhere or desquamate as readily leading to retained dead skin scale.
- This skin scale, or dander, creates an uneven skin surface. This has led to the concept of exfoliation, which uses chemical or mechanical means to encourage the removal of the dead skin scale.

The Eyelid

- The eyelid skin is some of
- the most interesting on the body. It moves constantly as the eyes open and close; thus, it must possess unique mechanical properties. It must be thin enough for rapid movement, yet strong enough to protect the tender eye tissues. Eyelid tissue shows the state of health and age of an individual more rapidly than any other skin of the body



The Eyelid

- Tired eyes, reflects the appearance of the eyes and the eyelids
- The eyelid skin appears to age quickly resulting in the presence of redundant upper eyelid tissue and lower eyelid bags



Anatomy and Physiology

- The eyelids are indeed composed of unique skin. It is the thinnest skin on the body, accounting for the eyelids as the most common site of irritant contact dermatitis and allergic contact dermatitis, either from products that are directly applied to the eyelids or from products transferred to the eyelids by the hands. The eyelid skin also has a paucity of sebaceous glands, making it a common area of skin dryness
- The eyelids are also a common source of symptoms induced by allergies. These
- symptoms can be itching, stinging, and/or burning. Most persons with these symptoms
- respond by vigorously rubbing the eyelids. This can cause mechanical damage to the
- eyelid skin, from minor trauma resulting in sloughing of portions of the protective stratum corneum to major trauma resulting in small tears in the skin.
- Most of the skin on the body responds by thickening or callousing when rubbed. Eyelid skin will also thicken, but this predisposes to decreased functioning and worsening of the symptoms

Anatomy and Physiology

- Eyelids are also a common site for cosmetic adornment. There are more individual
- colored cosmetics for the eyelid area than any other body area to include mascara,
- eyeliner, eye shadow, and eyebrow pencil. These cosmetics and the products used to
- remove them can be a source of both allergic and irritant contact dermatitis.



Common Dermatologic disease conditions

- the eyelid skin is the most common body site afflicted with irritant and allergic contact dermatitis.
- The eyes are also uniquely designed to sense substances that might cause vision damage, and thus the eyelids have a heightened immune response. Swelling induced by topical, inhaled, or ingested allergens are frequently seen initially in the eyelids. The thin nature of the skin also allows the swelling, due to tissue edema, to appear more dramatic than on other body areas where the skin is thicker and less mobile.
- A type of dandruff, known as seborrheic blepharitis, can also affect the eyelids

Common Dermatologic disease conditions

- The most common dermatologic disease to afflict the eyelid is eczema. Since the eyelid is relatively poor in oil glands, dry eyelid skin is frequently seen due to over-aggressive removal of lipids.
- This may be due to the use of a strong cleanser or products designed to solubilize oil-based waterproof cosmetics, such as mascara and eyeliner. Anything that damages the intercellular lipids or the corneocytes will result in eyelid eczema.
- Thus, eyelid hygiene must achieve a careful balance between the removal of excess sebum and old cosmetics to prevent eyelash infections and seborrheic blepharitis, while preventing damage to the intercellular lipids and ensuing eyelid eczema.

Hygiene Needs

- Cleansing of the eyelid tissue is indeed a delicate task. Typically, the skin should be handled very gently, due to its thin nature, and cleansing should remove excess sebum while preserving the intercellular lipids. If more aggressive cleansing is required, an appropriate moisturizer must be selected that will provide an environment for healing while the intercellular lipids are resynthesized.

The typical cleanser used in the eye area by dermatologists is baby shampoo. This non-stinging shampoo formula allows cleansing of the eyelashes to prevent seborrheic blepharitis, while minimizing further eyelid irritation.

- Typically, the cleanser is applied with the fingertips and not a washcloth or other cleansing implement, since the fingers can easily sense if too much pressure or force is being used to clean the thin eyelid tissue

Skin Care Needs

- After maintaining good eyelid hygiene through proper cleansing, the issues of moisturization and sun protection must be addressed. These are the skin care needs of the eyelid skin. The recurring theme throughout this discussion of the eyelid has been the unique thinness of the skin.

This consideration becomes extremely important when formulating eyelid moisturizers and sunscreens. Any eyelid moisturizer selected must spread easily to prevent bruising or tearing. Thus, highly lubricious emollient formulations are best. They should occlude the eyelid skin enough to allow the skin barrier to repair, but should not be too oily such that they interfere with vision if accidentally introduced into the eye.

- The thinness of the eyelid skin also makes the use of sunscreens important. UVA radiation can easily penetrate to the dermis of the thin eyelid skin, causing premature wrinkling.

The Lips

- The lips present many of the same challenges as discussed for the eyes.
- They both represent transitional skin between traditional keratinized dry skin and moist mucosal skin and they both are portals of entry for foreign invaders, such as bacteria and viruses, and other substances entering the body, such as medications



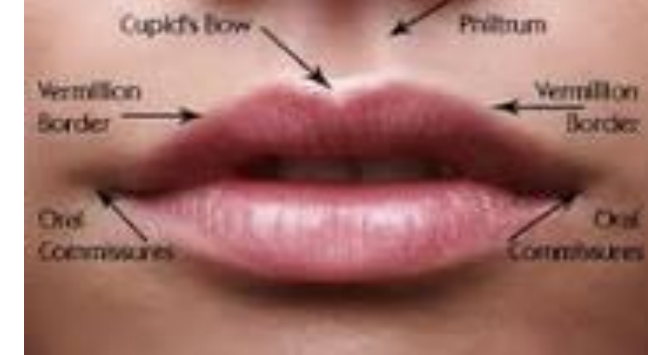Lips

The lips are much more complex in terms of the substances they contact, since the lips are instrumental in eating. They contact many different foods, chemicals, and cosmetics.

- They are also in constant motion, much more so than any other part of the body, due to their participation in the phonation associated with speech.
- Yet, their cosmetic value cannot be minimized. They are an instrument of affection as delivered by a kiss and the focal point of the face.



Anatomy and Physiology



- The lips must sustain pulling, twisting, and contracting forces in many different directions

in order to eat and speak. To accomplish this engineering feat, they contain a transitional

skin surface, known as the vermillion, overlying a complex array of muscles with supporting fat.

The vermillion is the portion of the lip that is visible and adorned by lip cosmetics. It has a rich vascular supply that is visible through the thin overlying skin. The lip skin is unique in that it does not have a well-developed stratum corneum making it different than the rest of opaque facial skin.

Damage to the lip tissue, from sun or cigarette heat, results in formation of a dysfunctional stratum corneum that causes the lips to lose their characteristic red color. This causes a whitening of the lips, medically known as leukoplakia, literally translated as white plaque.

Anatomy and Physiology

- As the lips age, they begin to thin and lose their characteristic shape. This is due to loss of the fat that gives the lip substance. A profile view of a child will reveal lips that
- protrude from the face, while the profile of a 70-year-old woman will reveal lips that are flat and even depressed from the facial surface. Many of the new cosmetic fillers, such as hyaluronic acid, are designed to replace this lost fat.



Common Dermatological Disease Conditions

- The lips not only are subject to the effects of aging, but also to the insults of dermatologic disease. Infection is probably the most common serious lip problem. This is typically due to the herpes simplex type 1 virus that is responsible for fever blisters. This infection is seen as a group of clustered tiny blisters, known as vesicles, at the margin of the red vermilion.
- The herpes simplex virus is usually contracted during youth and remains dormant under the watchful eye of the immune system until reactivated and allowed to migrate from the nerve root to the skin surface. The virus reactivates when the immune system is overburdened.

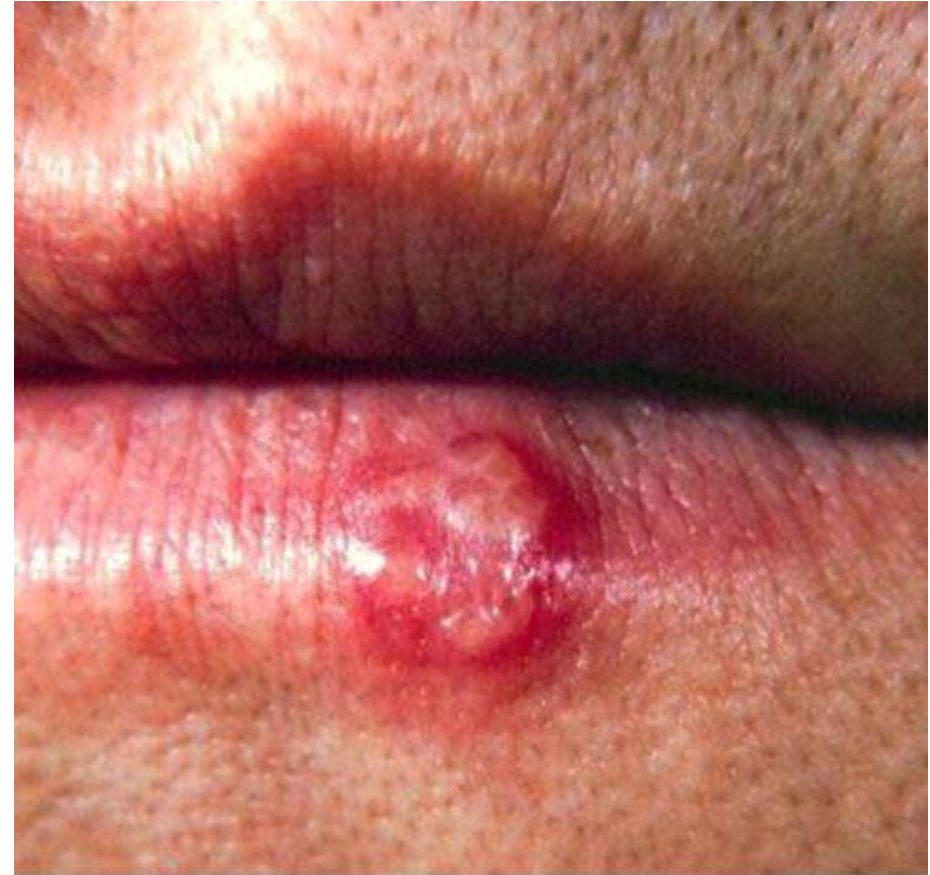
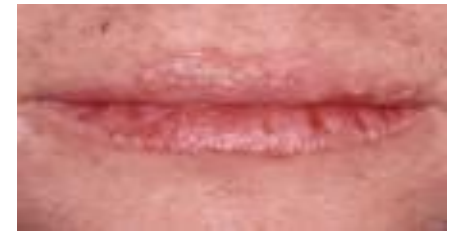
Photo courtesy of CDC - Dr. Herrmann

Common Dermatological Disease Conditions

- Yeast most commonly infects the corners of the mouth, a condition known as perleche. The corners of the mouth are a frequent site of saliva collection, especially in children who drool, adolescents with braces, and the elderly with poor dentition. The moisture remains in the mouth corners overnight, creating a condition known as maceration, and provides a perfect environment for the growth of yeast.
- The last common lip disease to be discussed is chelitis, which simply means inflammation of the lips. Chelitis can be due to chapped lips, a condition akin to dry skin.



Hygiene Needs

- From the preceding discussion, it is apparent that the lips have some unique hygiene needs, because they are the gatekeeper of everything that is consumed orally.
- Typically, the lips are washed with the face, but they are regularly cleansed with saliva. They are most frequently infected by direct contact with other infected individuals through kissing.
- Infection that enters the body through the mouth via hand/oral transmission is far more common than infection of the lips themselves.



Skin Care Needs

- The best method for keeping the lips infection free is to maintain the vermillion intact, free of fissures or openings. This requires the use of waxy, thick moisturizers designed to stay on the lips through saliva and food contact. The tiny yellow sebaceous glands that can be seen along the edge of the lips in elderly individuals do not function as abundantly with advancing age.
- Dry lips are also more common in the elderly due to nasal obstruction
- promoting mouth breathing and dentures that may not fit properly. Dry lips may also be seen at the other end of the spectrum in children who are endentulous or thumb suckers.
- Occlusive lip balms that prevent saliva from repeatedly wetting the skin surface are the most successful at alleviating the dry skin.


The Hands



- The hands are one of the most expressive parts of the body, providing the structures needed to write, draw, paint, dance, and express affection.

The Hands

- It is frequently said that much can be said about people from their handshake, which is an assessment of the skin, muscle, and bone that form the hand. The hand can express gender, occupation, and age.



The Hands

- Female hands are small while male hands are large and muscular. People who work with their hands outdoors have a much different skin feel than persons who type on a computer for much of the day.
- Children have soft, doughy, padded hands while the elderly have thin, sinewy, bony, arthritic hands.

The infographic is divided into two main sections. The top section, titled 'Index finger and ring finger of equal length', shows two hand silhouettes labeled 'Male' and 'Female'. Below them, text explains that in women, the ring and index fingers are equal in length, while in men, the index finger is shorter. This section is further divided into two columns: 'MEN' and 'WOMEN', each with a photograph of a hand and a list of associated traits. The bottom section, titled 'Index finger shorter than ring finger', also has two columns for 'MEN' and 'WOMEN' with photographs and trait lists.

Male **Female**

In women, the ring finger and the index finger tend to be about the same length. But in men, the index finger is usually the shorter of the two digits.

Index finger and ring finger of equal length

MEN	WOMEN
<ul style="list-style-type: none">■ Lower levels of autism and ADHD, more studious■ Higher levels of early heart disease■ Lower fertility■ Lower level of musical ability■ Lower testosterone levels and a higher risk of testosterone deficiency syndrome	<ul style="list-style-type: none">■ Higher fertility■ Higher risk of breast cancer■ Lower levels of autism■ Less promiscuous and fewer sexual partners■ Lower levels of ADHD

Index finger shorter than ring finger

MEN	WOMEN
<ul style="list-style-type: none">■ Tendency toward alcoholism, aggression■ More athletic ability in soccer, rugby, basketball, skiing and football■ Larger number of sex partners■ Five times higher profits for financial traders■ More attractive and symmetrical (but not more masculine) face	<ul style="list-style-type: none">■ Promiscuous sexual proclivities■ Higher levels of anorexia and bulimia■ Higher levels of homosexuality■ Higher athleticism■ Delayed puberty

The Hands

- Hands are what make humans unique from every other living thing on the earth.



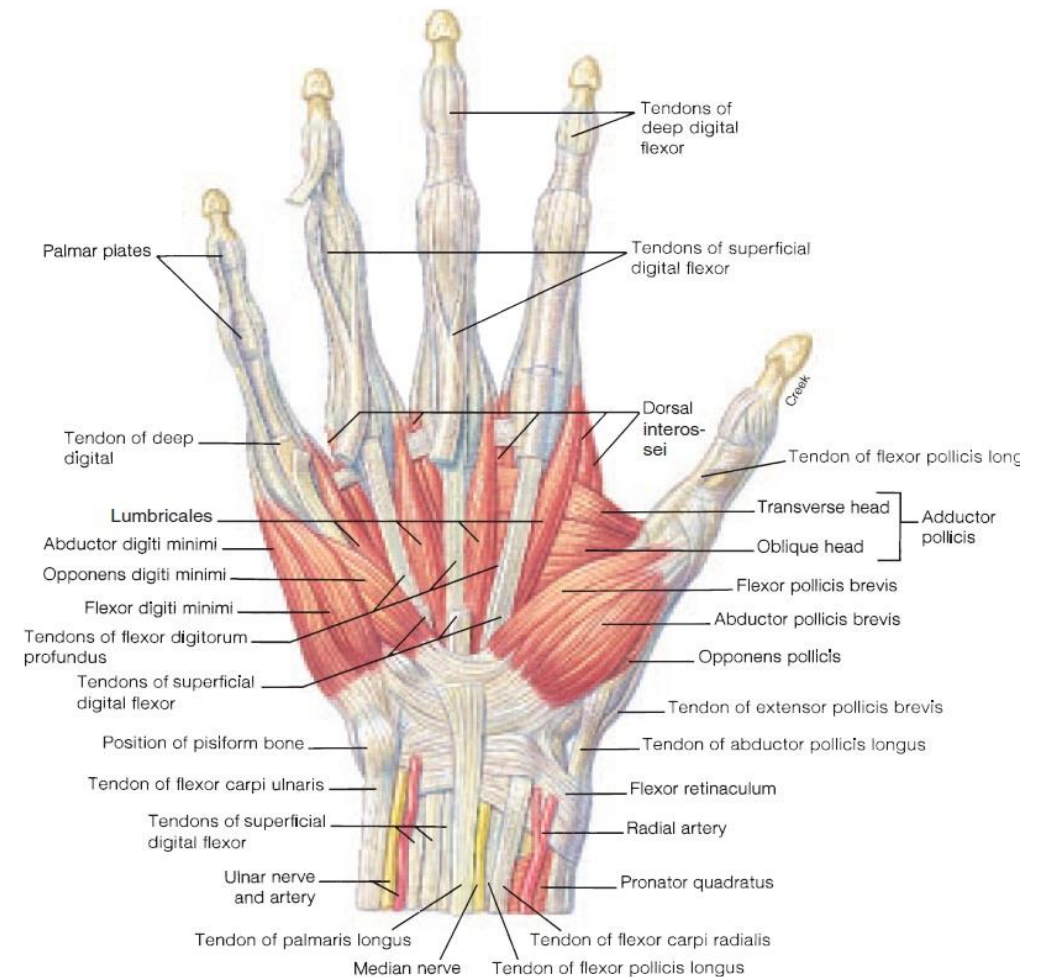
www.shutterstock.com · 527034535

Anatomy and Physiology

- The hands are formed of many tiny muscles and bones that account for their agility. They are that part of the body that most frequently touches the outside world and can serve as a vector, bringing infection to the vulnerable nose, eye, and mouth tissues.
- The hands also sustain considerable chemical and physical trauma.
- They are washed more than any other body area, yet are completely devoid of oil glands on the palmar surface.
- While the stratum corneum of the palm is uniquely designed to withstand physical trauma, it is not designed to function optimally when wet. Water destroys the resistive physical strength of the palmar skin, which is why hand blisters are more common when the hand is perspiring heavily.

Anatomy and Physiology

- The hands are formed of many tiny muscles and bones that account for their agility. They are that part of the body that most frequently touches the outside world and can serve as a vector, bringing infection to the vulnerable nose, eye, and mouth tissues.
- The hands also sustain considerable chemical and physical trauma.

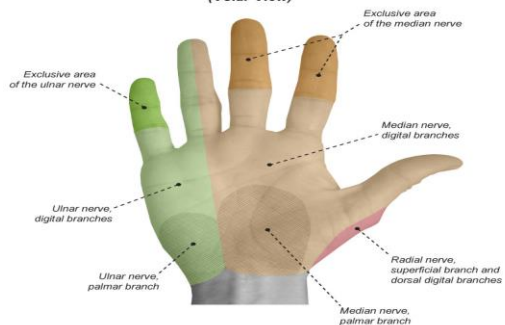


(a)

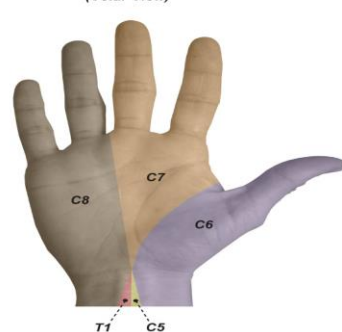
Anatomy and Physiology

- The palmar surface of the hand has numerous sweat glands, known as eccrine glands, which are largely under emotional control. Palm sweating may occur in warm weather, but may also occur under stressful conditions.
- The hand responds to trauma by forming thickened skin, known as a callus. Calluses are formed from retained layers of keratin that form a dead skin pad over the area subjected to repeated physical trauma.

Sensory Territories and Innervations
(Volar View)



Dermatomes
(Volar View)



Common dermatological disease conditions

- Dermatologic disease needs to be divided into those conditions that affect the dorsum or back of the hand and those that affect the palm of the hand. This is an important distinction because the two skin surfaces are quite different.
- The dorsum of the hand is thinner skin that becomes increasingly thinner with age. After the face, the back of the hand is generally the most photoaged skin location.
- The skin of the hand loses its dermal strength early leading to decreased skin elasticity, which can be simply measured by pinching the skin on the back of the hand and watching for the amount of time it takes for the skin to rebound to its original conformation. This easy to perform test is an excellent measure of the hand skin age.

Common dermatological disease conditions

- Skin that takes a long time to return to normal configuration is more photoaged than youthful skin that bounces back energetically. In addition to losing elasticity, photoaged skin also becomes irregularly pigmented leading to dark areas, known as lentigenes, and light areas, known as idiopathic guttate hypomelanosis.
- This irregular pigmentation is also accompanied by skin that is easily injured. Injury may be seen in the form of red bruises, affectionately named senile purpura, and tissue tears from minimal trauma, which heal with unattractive white scars.



Common dermatological disease conditions

- The palm of the hand is affected uniquely by inflammatory conditions like eczema and palmar psoriasis. Because the palm is the surface that the body uses to pick and touch, it more commonly is affected by chemical and physical trauma. This trauma may manifest as hand eczema, which is usually treated with high potency corticosteroids.
- In addition, highly occlusive and emollient hand creams are necessary to rehydrate damaged keratin and create an optimal environment for barrier repair. Hand creams are also important in the treatment of psoriasis where too much poor quality skin is produced too quickly.
- Both of these conditions require carefully selected cleansers and moisturizers, in addition to prescription therapy.
- The palms can be affected by excessive sweating, a condition medically known as hyperhidrosis

Hygiene Needs

- The hands receive more cleansing than any other part of the body. The basic ritual of “wash your hands before you eat” is an effective method of preventing disease transmission, but may take its toll on the physiologically sebum-lacking skin of the palms.
- Excessive hand washing can even be considered a medical disease, especially in persons with obsessive-compulsive disorder.

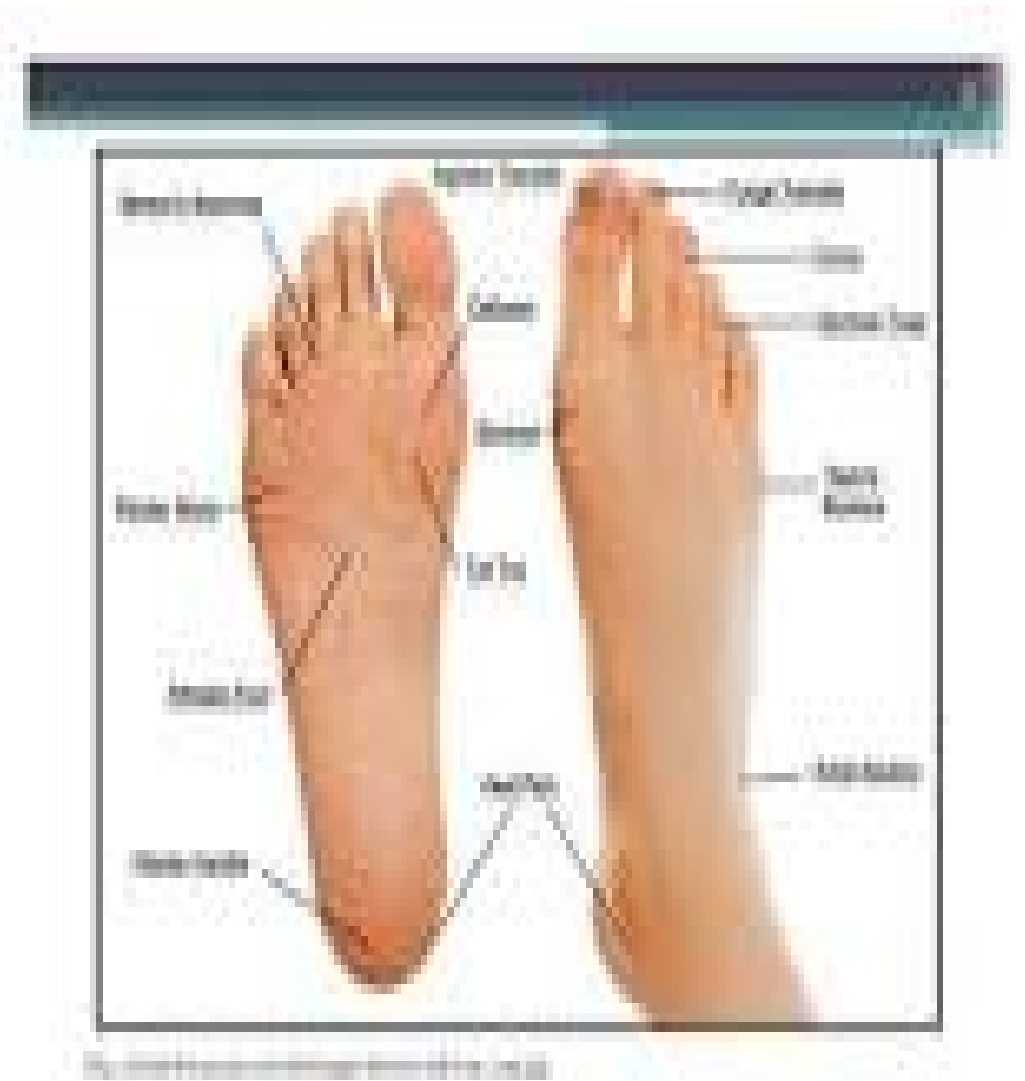


Skin Care Needs

- The skin care needs of the hands go beyond basic cleansing to moisturization, healing, photoprotection, and skin lightening.
- Hand moisturization is very important due to frequent cleansing. **Hand moisturizers should be designed to occlude the skin reducing trans-epidermal water loss, rehydrate the skin through the use of humectants, alleviate itch and pain, and smooth the skin surface with emollients.**
- **In addition to moisturization, the hands also need photoprotection** both during sports and while driving a car, since photoaging UVA radiation passes through the windshield of a car.
- Sun protection is a unique challenge for the hands because they are frequently aggressively washed, removing the sunscreen. However, the need for sun protection is obvious when one considers the thin dyspigmented skin that characterizes mature hands.
- This means that the hands require aggressive anti-aging therapy

The Feet

- The hands and the feet have much in common. They both have a different type of epithelium on the dorsal and plantar surface, they both have hair on the dorsal surface and none on the plantar surface, and they both have few sebaceous glands and numerous sweat glands on the plantar surface.



The Feet

- However, there are many differences between the hands and the feet, the most important being that the feet constantly bear the weight of the body while the hands do not. The feet are used for locomotion, competitive athletics, and personal expression in the form of dance. They are forced into shoes that can function both as protection while walking and the source of bony deformity.
- One only need look at the bunions and overlapping toes of the woman who wore tall, spiked heel, pointed toe shoes during her youth who cannot walk normally today due to misshapen feet that cannot properly bear weight.



Anatomy and Physiology

- The feet form our most important point of contact between the body and the earth. They grow proportionately as we grow during adolescence, pregnancy, and old age to provide the body with stable balance. Unfortunately, their bones wear out with continued use and chronic inflammation to yield crippling arthritis.
- The sole of the foot is made of keratin remarkably resistant to trauma from torque and pressure, but this resiliency is decreased when the keratin is wet. This most commonly occurs in individuals with sweaty feet. The interaction of sweat with the plantar keratin in the environment of the shoe creates unique hygiene challenges.
- The lack of oil glands on the sole of the foot also predisposes it to dry skin.

Diference Between Male and Female Feet

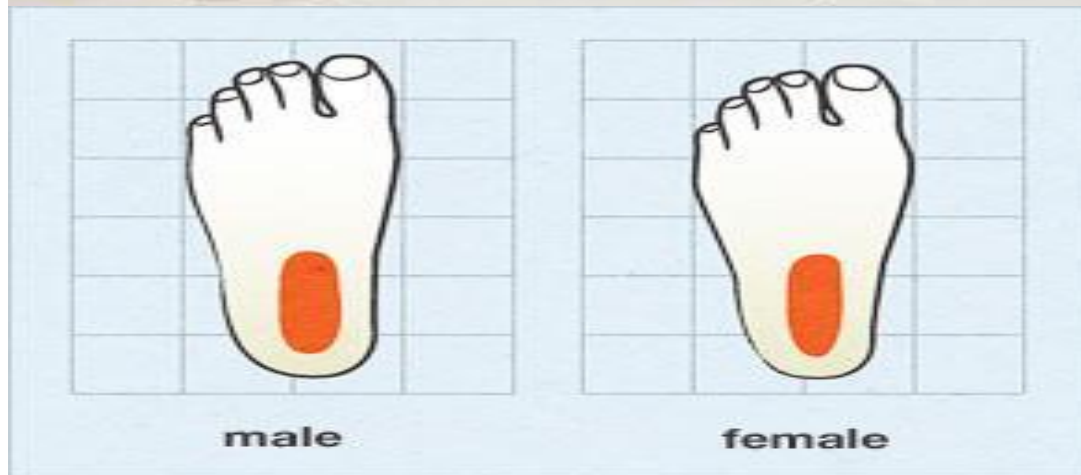


Tabela 3 – Médias (dp) e variações (valores mínimos e máximos) dos parâmetros avaliados nos pés masculinos e femininos e respectivas comparações.

Parameters	Sexo		Independent Student's t test
	Male (SD) (n = 166)	Female (SD) (n = 166)	
M I	125.40 (8.28) 100 – 153	115.13 (7.44) 99 – 133	p < 0.001 *
M II	127.81 (8.23) 102 – 153	117.55 (7.35) 102 – 137	p < 0.001 *
M III	123.36 (8.06) 99 – 146	113.46 (7.25) 98 – 132	p < 0.001 *
M IV	114.22 (7.74) 94 – 135	105.34 (7.28) 91 – 124	p < 0.001 *
M V	99.55 (7.98) 81 – 120	91.68 (7.47) 75 – 117	p < 0.001 *
Forefoot width	87.05 (5.63) 70 – 101	80.82 (4.65) 66 – 95	p < 0.001 *
Forefoot width/MII index	0.683 (0.048) 0.529 – 0.832	0.689 (0.044) 0.595 – 0.804	p = 0.215

Source: HRM-LA; HGF-LA - M – metatarsal – mean length, min – max - SD – standard deviation - (n) – number of subjects.

Common Dermatological Disease Conditions

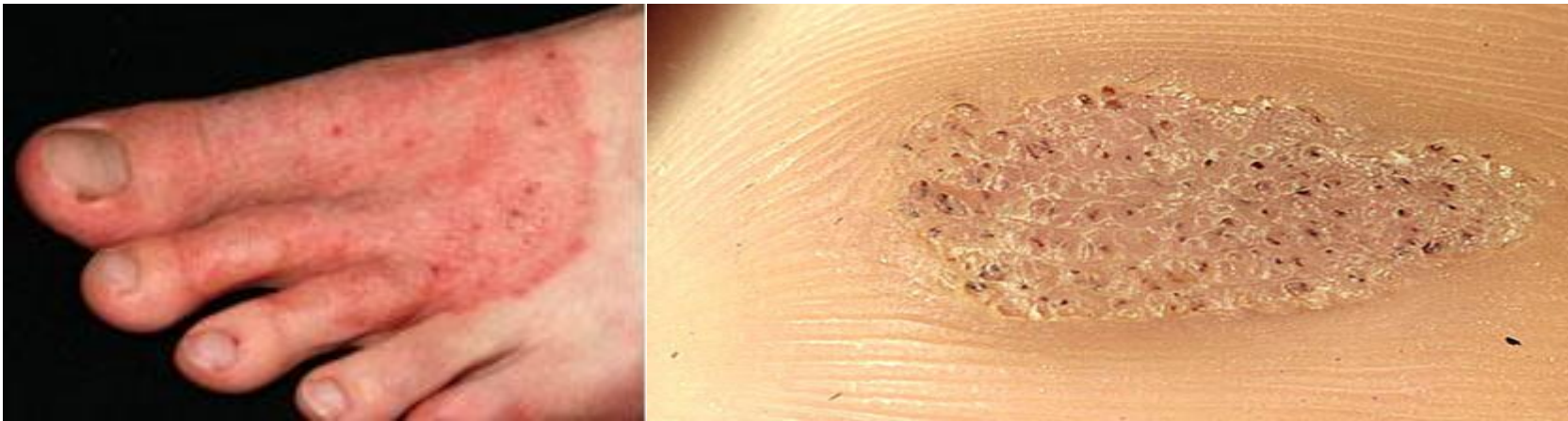
- The warm, moist, dark environment of the foot in the shoe is perfect for infection of all types, especially between the toes. The foot is a common site for bacterial, fungal, and yeast infections. These organisms can live on the surface of the foot or enter into the body through small wounds.
- Foot infection is a major medical issue in diabetics who have a reduced capacity to fight infection, poor blood circulation to the feet, and reduced sensation.
- In normal individuals, the most common infection of the feet is fungal, a condition known as tinea pedis.

Common Dermatological Disease Conditions

- Tinea pedis most commonly occurs between the toes, especially between the fourth and fifth toes, since these toes are usually closely spaced. Mild infections of this type can occur in otherwise healthy athletic individuals;
- The incidence of fungal infection increases with advancing age due to deterioration of the body's immune system. Most fungal infections of the toes or the sole of the foot can be easily treated with two weeks of a topical antifungal. However, fungal infections of the nail require oral medication, usually for three months.

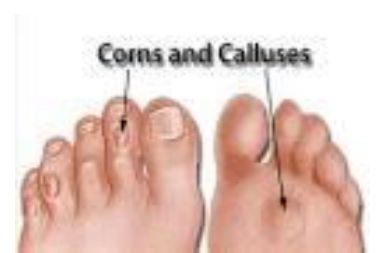Common Dermatological Disease Conditions

- The foot is also the site of frequent viral infections in the form of plantar warts. The highly infectious human papilloma virus causes warts. This virus only affects humans, thus warts are passed by person-to-person contact through wounds in the foot. Common places to contract warts include public pools, exercise facilities, dance studios, public showers, etc., basically any place where there is moisture and lots of bare feet.



Common Dermatological Disease Conditions

- Other noninfectious growths that occur on the foot include calluses and corns.
- Calluses form over areas of the feet that are commonly traumatized, such as the side of the great toe, the side of the little toe, and the heel.
- Corns, on the other hand, occur over bony prominences. Hard corns occur on the sole of the foot at the base of the toes while soft corns occur over bones between the toes.
- Both calluses and corns are deposits of excess keratin designed to protect the foot from undue injury while walking. Unfortunately, they may produce pain while walking. Substances can be applied to the growths to remove the keratin, but the callus or corn will return unless the exact cause for their formation has been determined. This can be ill-fitting shoes, arthritic changes, or improper weight transfer over the foot while walking.



Common Dermatological Disease Conditions

- The foot is also a common site for eczema or dry skin due to the complete lack of oil glands on the sole and the reduced number of oil glands on the top of the foot.
- The feet receive the most cleanser and water contact of any part of the body while showering, thus excessive removal of sebum on the feet is common.
- For all of the reasons put forth here, the feet have unique hygiene needs to balance the predilection for infection with the dryness of overcleansing.

Hygiene Needs

- The feet need aggressive hygiene, not only to prevent infection, but also to control odor.
- Foot odor is primarily due to the mixture of sweat with bacteria in the closed environment of the shoe. Bacteria digest the sweat to obtain nutrition and reproduce.
- Most individuals have several types of bacteria present in low numbers on the feet. The difference between individuals with minimal foot odor and extreme foot malodor is the number and type of bacteria present on the feet.
- Foot malodor is a much greater problem in persons with hyperhidrosis. Hyperhidrosis of the feet is identical in cause to hyperhidrosis of the palms, in that both are primarily under emotional control, although feet tend to sweat more for thermoregulatory purposes due to the presence of warm socks and shoes.

Hygiene Needs

- Good cleansing of the feet is a prerequisite to skin health, but overly aggressive cleansing may set the stage for dry skin and foot eczema. Thus, **foot cleansing must be carefully balanced with proper moisturization.**

Skin Care Needs

- One way to minimize the dryness that may be associated with foot cleansing is through the use of moisturizers.
- Moisturizers can be used to prevent foot dryness and soften calluses utilizing substances such as urea and lactic acid to open up water binding sites on dehydrated keratin. The physical act of rubbing a moisturizer on the feet can also help desquamate dead skin that may build up between the toes and on the arch of the foot, especially in elderly individuals.
- **Foot moisturizers must be similar to hand moisturizers in that both occlusive and humectant substances must be incorporated**

Nails and Cuticles

- In certain cultures, the fingernails are used to designate class status. For example, Greek males allow their little fingernail to grow longer than the rest to show that they work at a desk job rather than performing manual labor, since a long little fingernail cannot be maintained if people use their hands to make a living.
- Similarly, women in United States use long nails for much the same purpose. Since the nails are made of nonliving tissue, their cosmetic needs are much different than any of the other body areas previously discussed.

Nails and Cuticles

- No discussion of the hands and feet would be complete without consideration of the nails and cuticles. Even though the nails are made of nonliving keratin, they are the source of considerable cosmetic attention.
- Manicures, pedicures, artificial nails, nail polish application, etc. are all popular activities. Certainly, the nails add glamour and enhance the appearance of the hands and feet.



Nails and Cuticles

- In certain cultures, the fingernails are used to designate class status. For example, Greek males allow their little fingernail to grow longer than the rest to show that they work at a desk job rather than performing manual labor, since a long little fingernail cannot be maintained if people use their hands to make a living.
- Similarly, women in United States use long nails for much the same purpose.
- Since the nails are made of nonliving tissue, their cosmetic needs are much different than any of the other body areas previously discussed.



Anatomy and Physiology

- The nail is a thin plate of nonliving keratin designed to protect the tip of the finger and toes.
- The nail is produced by a group of cells designated as the nail matrix that lies approximately one-quarter inch below the visible nail. The nail matrix cells are formed at birth and cannot regenerate following injury. For this reason, trauma to the nail matrix can result in a permanently deformed nail that cannot repair and will not grow normally.
- One of the most important structures adjoining the nail from a dermatologic standpoint is the cuticle. The cuticle is a like a rubber gasket forming a watertight seal between the nonliving nail and the skin of the fingertip.
- Damage to the cuticle results in water, chemicals, or anything the hand touches reaching the nail matrix cells. It is for this reason that dermatologists recommend that the cuticle not be dislodged, pushed back, trimmed, or manipulated in any way.
- Many of the abnormalities and diseases of the nail tissue can be traced back to a damaged cuticle.



Common Dermatological Disease Conditions

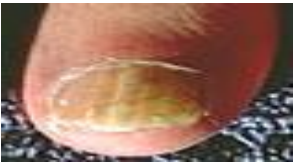- Nail abnormalities and disease are extremely hard to treat because the visible nail cannot be repaired; only the growth of new nail can be influenced. In most individuals, it takes six months to grow a new fingernail and one year to grow a new toenail.
- This means that creation of a new nail to replace a damaged nail is a long process requiring patience before the effects of successful treatment are visible.
- The common nail problem is loosening of the nail plate from the nail bed, a condition known as onycholysis.

Common Dermatological Disease Conditions

- Onycholysis is usually traumatic in nature and is more common in individuals who wear artificial nails in the form of sculptures or tips.
- The bond between the artificial nail and the natural nail is stronger than the bond between the natural nail and the underlying skin. This means that the natural nail plate will rip from the skin causing pain and swelling of the finger.
- The natural nail now appears white, because the nail is no longer attached to the pink flesh, and a space is created beneath the nail plate and the skin where infection can occur.
- Onycholysis is the most common condition predating a nail fungal infection.

Common Dermatological Disease Conditions

- Fungal infections of the nail, medically known as tinea unguinum, are extremely common with advancing age. It is estimated that 80% of persons age 80 or older will develop a nail fungal infection.
- The infection becomes more common with advancing age as the immune system's ability to protect against a fungal invader is diminished. The same fungus that causes infection of the feet also causes nail fungus.
- Nail fungal infections of the hands and feet are very difficult to treat since medication cannot be administered to the nonliving nail. The site of the nail fungal infection is not actually the nail itself, but the living tissues beneath the nail.
- This makes topical treatment minimally effective because any topically applied medication must penetrate the hard nail plate to reach the infected tissues below.



Common Dermatological Disease Conditions

- For this reason, fungal nail infections are traditionally treated orally with medications that must be taken for three months. The oral medication allows an antifungal to be incorporated into the newly grown nail, forming a barrier for the advancing fungal infection.
- The old infected nail is then cut away to physically remove the infected nail plate, and eventually the treated nail, resistant to fungal invasion, is formed.
- However, the nail containing the oral antifungal medication is removed with further nail growth and reinfection commonly occurs.

Common Dermatological Disease Conditions

- Nail fungus is actually transmitted through fungal spores which are extremely resistant to destruction. Traditional disinfectants used to clean manicure and pedicure instruments are ineffective against the spores, thus fungal disease can be transmitted through nail salons.
- Nail fungus is also not susceptible to triclosan or other antibacterial agents traditionally used in soaps and cleansers. Thus, the best protection against a nail fungus infection is an intact nail and surrounding cuticle.

Common Dermatological Disease Conditions

- Another common nail problem is peeling and cracking of the nail plate. While these are largely cosmetic concerns, they can result in pain and leave the nail weakened to infection. Nail peeling and cracking are more common with advancing age. This may be due to decreased blood flow to the cells of the nail matrix from arthritis or blood vessel disease or due to declining nutritional intake.
- The body certainly recognizes that the nails are not essential to maintain life, thus under times of stress or illness nail growth is not optimal. However, there are conditions where nutrients may not be absorbed from the intestinal tract that becomes more common with advancing age.
- One of these nutrients is biotin. Biotin is necessary for hard nails and may not be properly absorbed. For this reason, one of the main treatments for peeling, cracking nails is an oral biotin supplement.

Common Dermatological Disease Conditions

- There are a variety of inherited or acquired nail deformities for which no treatment exists. For this reason, many dermatologists run the other way when a patient presents with nail problems.
- Probably the common somewhat treatable nail deformity is psoriasis. Psoriasis is the production of too much poor quality skin too quickly. Psoriasis of the nail is similar in that the nail that is produced is also poor quality such that little chunks of the nail plate fall out leaving tiny holes or pits. Thus, the hallmark of nail psoriasis is pitted nails.
- The nails improve slowly as the body psoriasis improves, but methods of camouflaging the problem with nail polish or artificial nails are a more rapid solution. Most dermatologic nail conditions are best treated in the short term with cosmetic techniques

Hygiene Needs

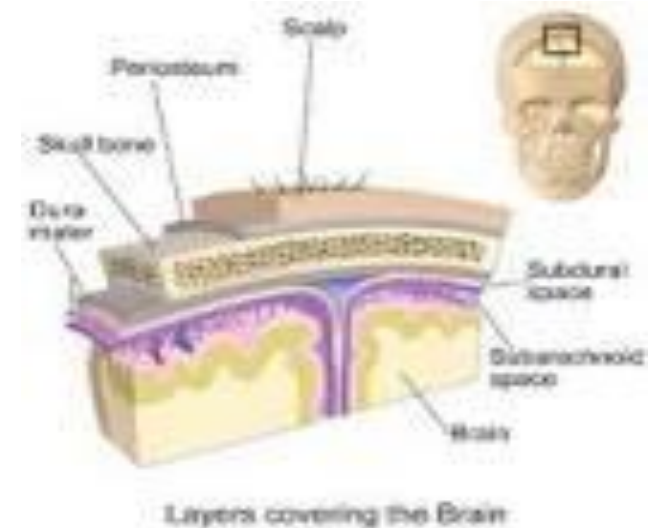
- As mentioned previously, the most important way to keep the nail plate healthy is to leave the cuticle undisturbed. For some, this answer is almost too simple. The nail is designed to take care of itself, and any manipulation interferes with the perfect design.
- Typically, hand hygiene and nail hygiene are taken care of simultaneously with good hand washing.
- The most common infection that affects the nail is known as a paronychia. A paronychia is actually an infection of the skin surrounding the nail to include the cuticle.
- Here the cuticle is disrupted and water enters the tissue around the nail. This forms a warm, dark, moist space perfect for the growth of yeast organisms. The yeast breakdown the skin and make an environment appropriate for bacterial infection, which occurs secondarily.
- The bacteria then multiply and produce pain and pus. Use of antibacterial cleansers containing triclosan are very helpful in preventing a paronychial infection along with good moisturization of the tissues around the nail to prevent cracking. Oral antibiotics are usually required to treat nail and cuticle infections of this type.

Skin and Nail Care Needs

- Moisturizing the nail and the cuticle are important to prevent disease. Usually these structures are moisturized at the same time the hands are moisturized, but there are some key differences to consider.
- The outer stratum corneum layer of the skin of the hands is replaced every two weeks, but the nails are nonliving, thus, any dehydration damage inflicted is permanent. Remoisturizing the nails can be minimally enhanced with urea and lactic acid, which increase the water binding sites on the nail keratin, but their effect is temporary until the next hand washing. Also, too much urea and lactic acid can over soften the nail plate, making it more susceptible to fracture.
- Water is the main plasticizer of the nail plate and it should not be removed with aggressive cleansing.

The Scalp

- The scalp/hair interface is very similar to the nail/cuticle interface in many respects. Here the nonliving hair abuts the living scalp, just like the nonliving nail abuts the living cuticle.
- The skin needs of the scalp are complex due to the presence of abundant sweat, sebum, and nerves all complicated by the presence of numerous hair follicles



Anatomy and Physiology

- It is important to recognize that healthy hair begins with a healthy scalp. The hair grows actually below the skin of the scalp with follicles protected in the subcutaneous fat covering the skull.
- The scalp has an abundant blood supply to provide the necessary nutrients for hair growth and an extensive nerve network. This is why injuries to the scalp bleed profusely and are quite painful. In addition to blood vessels and nerves, the scalp also has numerous eccrine sweat glands and sebaceous glands. These secretions provide nutrients for bacteria and fungus that can infect the skin of the scalp.
- The hair also increases the chances for infection by providing abundant surface area for organisms to grow.
- Lastly, sweat can function as an irritant, accounting for the frequent itching associated with areas of sweat collection, such as the nape of the neck.
- The presence of the neural network around the hairs also provides more opportunities for sensation of itch to be induced.

Common Dermatological Disease Conditions

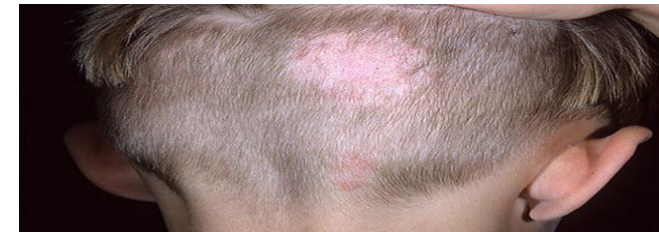- The scalp is the site of many dermatologic diseases, the most common of which is dandruff.
- Dandruff lies on a spectrum between occasional mild flaking of the scalp to thick oozing plaques devoid of hair, known as seborrheic dermatitis. Both of the conditions are caused by the same fungal organism named *Malassezia globosa*.
- This fungal organism is present in the air and lands on the scalp rich in sebum. It consumes the sebum and leaves behind free fatty acids that are extremely irritating to the scalp skin.
- These free fatty acids induce itching, inflammation, and increase the scalp skin turnover resulting in flaking. If the immune system is intact, the body will not allow the *Malassezia* to proliferate and the skin remains healthy.

Common Dermatological Disease Conditions

- If the immune system is not intact, such as with advancing age, the presence of illness, or human immunodeficiency virus (HIV) infection, the Malassezia organisms will multiply and their sheer number will induce an infection.
- A mild infection may be perceived as dandruff, but a more severe infection is termed seborrheic dermatitis.
- **The key to preventing a Malassezia scalp infection is the use of topical antifungals in the form of shampoos containing zinc pyrithione or selenium sulfide or ketoconazole. Active infection can be treated with prescription oral and/or topical antifungals**

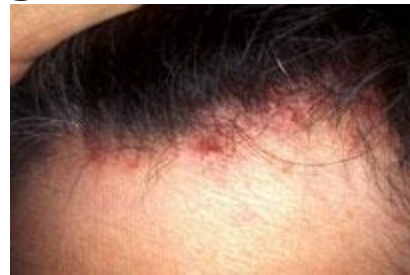Common Dermatological Disease Conditions

- Other fungal organisms, besides *Malassezia*, could also infect the scalp. These include the same fungal organisms that cause athlete's foot (*tinea pedis*) and nail fungal infections (*tinea unguinum*).
- Fungal infections of the scalp, medically known as *tinea capitis*, are commonly termed ringworm. A worm is not involved, but the areas of hair loss are round, hence the early misnomer that a round worm was causing the problem.
- The organisms that cause scalp fungal infections can be transmitted person to person on combs or through direct contact.
- For this reason, *tinea capitis* is mainly seen in children. It is a highly contagious infection requiring the use of oral prescription antifungal medication for eradication.



Common Dermatological Disease Conditions

- Bacteria can also affect the scalp creating an infection known as folliculitis. In this condition, the bacteria enter the scalp at the site where the hair exits the scalp, known as the follicular ostia.
- Folliculitis is a common complication of an itchy scalp. Folliculitis is usually treated with shampooing for good scalp hygiene, treatment of the scalp itch with topical corticosteroids, and oral antibiotics for the scalp bacterial infection.
- Shampoos and scalp products that prevent itch are important for maintenance therapy, since an itchy scalp is usually the initiating factor for scalp folliculitis.

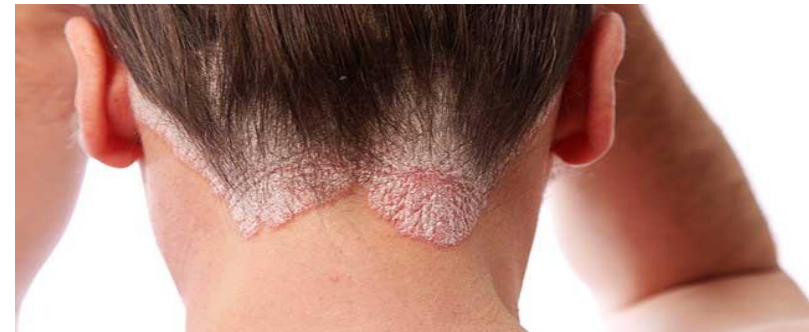

Common Dermatological Disease Conditions

- Psoriasis of the scalp is due to the production of too much poor quality skin too quickly. It presents with severe thick silvery plaques of scalp scale that may interfere with hair growth.

It is best treated medically; however, shampoos and scalp solutions containing keratolytics, such as salicylic acid, or anti-inflammatories, such as tar derivatives, are helpful.

- Antidandruff preparations, may be helpful since the presence of *Malassezia* may initiate a flare of scalp psoriasis.



Hygiene

- The hygiene of the scalp must be maintained while beautifying the hair, which can be a cosmetic challenge.
- Cleanliness of the scalp is very important to prevent fungal and bacterial infection that can induce subclinical and clinical disease, without over drying the nonliving hair. It is interesting to note that shaving the hair, which provides a ready surface for infection, can cure many scalp diseases. Though, this is not an alternative that would be considered by many.

Skin Care Needs

- The skin care needs of the scalp are to remove excess skin scale, loosen shedding hair, and maintain the biofilm of sweat, sebum, and organisms in balance.
- Many might suggest that the scalp should be moisturized to smooth down the skin scale and allow barrier repair to occur. While this is generally the case in other body areas, this logic does not pertain to the scalp. Skin scale provides a home for the fungal and bacterial organisms and allows sweat and sebum to accumulate on the scalp.
- Removal of the skin scale is key to scalp skin health.

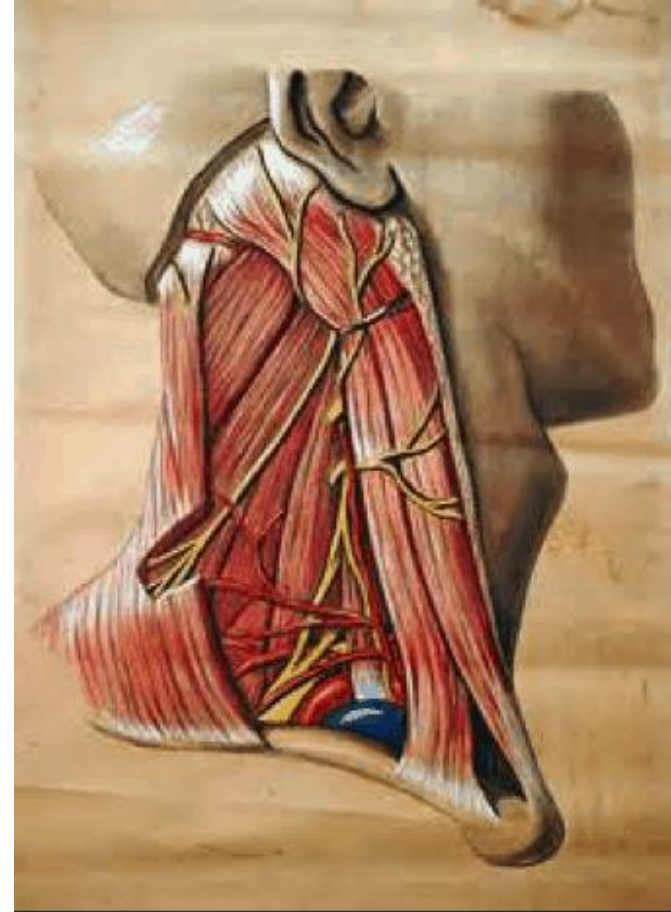The Neck

- The neck is an interesting area of highly mobile skin that provides a transition between the thin skin of the neck and the thicker skin of the upper chest and back.
- It contains fully mature hairs in the male and thin vellus hairs in the female. It is an important area from a cosmetic standpoint since it is an area affected by shaving in the male, fragrance application in the female, and photodamage in both sexes.



Anatomy and Physiology

- The neck skin covers important underlying structures, such as the blood and nerve supply to the head. The neck also contains the cervical spine and numerous muscles allowing the head to move side to side. It is for this reason that the neck is a difficult area cosmetically.
- It does not heal well from cosmetic surgical or traumatic injuries due to this continuous movement. It is also subject to photodamage, since many forget to wear protective clothing or apply sunscreen to the neck. Most hats do not provide adequate neck protection, thus the neck skin tends to show age more quickly than other body areas.



Common Dermatological Disease Conditions

- The photodamage condition that most commonly affects the neck is known as poikiloderma. Poikiloderma describes the thinned skin present from lost dermal collagen.
- It resembles chicken skin because the lower dermal oil glands become more visible as little tiny yellow dots. The thinned skin also allows better visualization of the underlying small vessel network creating the “red neck” terminology, used to describe those who work out of doors,
- Lastly, poikiloderma describes the irregular pigmentation that results from prolonged photodamage characterized by both lighter and darker areas in almost a lace-like pattern. It is interesting to note that the neck skin beneath the chin is sun protected. For this reason, neck photodamage is almost in the shape of a butterfly being more pronounced on the sides of the neck. The degree of photodamage present on the skin of an individual can be easily determined by comparing the sun protected skin beneath the chin with the appearance of the sun damaged skin on the sides of the neck.

Common Dermatological Disease Conditions

- The neck is also the site where women apply fragrance. For this reason, the neck is a common site of fragrance allergy. This allergy can manifest as allergic contact dermatitis, which presents as red skin with little tiny bumps, known as papules, and blisters, known as vesicles.
- Patch testing fragrances is usually performed to determine the exact cause after treatment with topical corticosteroids. Fragrances can also cause irritant contact dermatitis, which presents as simply red, itchy skin, due to the drying volatile vehicle in the perfume.



Hygiene Needs

- Similar to the rest of the body. The neck does not contain many oil glands and thus cleansing should be thorough, but not over drying. Probably the most unique hygiene need for the neck area is in males who shave the hair in this location.
- The neck is a transition area for hair growth between the beard of the face and the body hair of the chest. For this reason, the hair exits the skin in many different directions, which predisposes to inflammation of the hair follicular ostia, more commonly known as razor burn.
- Severe razor burn accompanied by ingrown hairs in African-American males is known as pseudofolliculitis barbae. In this condition, the curved hair shafts re-enter the skin causing inflammation and infection. It is a difficult condition to treat.
- Growing a beard and not shaving obtain the best results, since the long hairs cannot ingrow. The second best option to shave frequently and keep the hairs so short that they cannot ingrow.

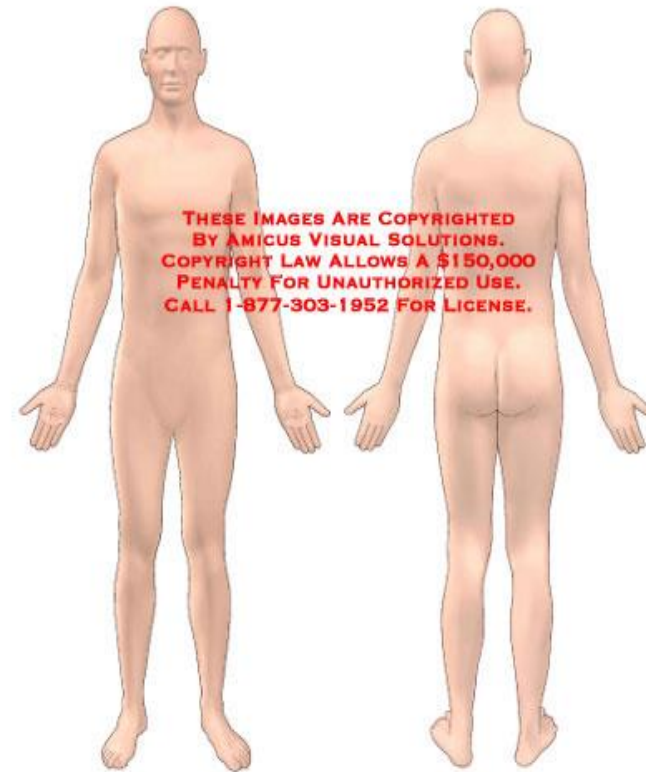
Skin Care Needs

- **The major skin care needs of the neck are good moisturization accompanied by sun protection.** The neck receives almost as much sun as the face and is a common site for precancerous and cancerous growths.

The Body

- The body encompasses all the rest of the skin not previously discussed, except for the skin fold areas.
- Most notable body areas for discussion are the back, chest, arms, and legs.
- The skin on the body does not heal as well as the face and neck. The further the skin is away from the face, the poorer the surgical result.
- This is due to the thicker skin in these locations accompanied by the distance away from the heart and a poorer blood supply

Surface Anatomy

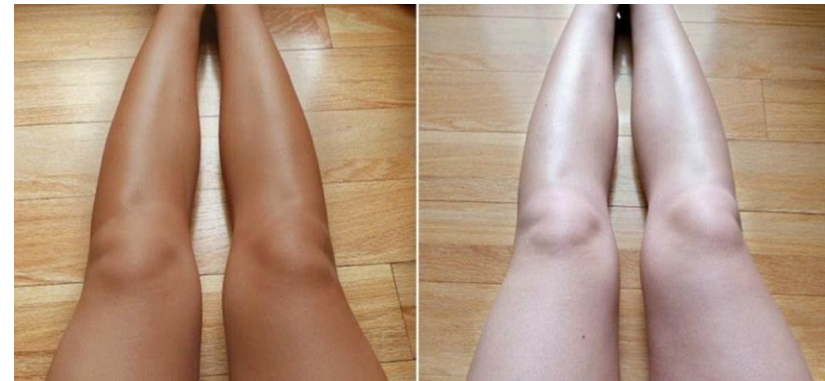

Anatomy and Physiology

- The thickest skin of the body is present on the upper back due to the need to sustain pulling and twisting movements from arm motion. This thick skin does not heal well and is a common site of unsightly scars.
- The poorest healing parts of the body are the upper chest, upper arms, and upper back where hypertrophic scars (thickened scars) and keloids (scars that extend beyond the boundary of the injury) may form with increased frequency.
- Oil glands are also reduced in these areas making careful cleanser selection and the use of moisturizers important.

Anatomy and Physiology

- One of the itchiest spots on the entire body is at the base of the shoulder blade on the back. It is not quite clear why is this the case; however, this spot is extraordinarily difficult to reach and is a common place where people routinely rub against a doorframe!
- The arms and legs form another anatomic area. Both sites possess skin that is designed for movement accompanied by hair growth. The oil glands are more numerous here than on the back and chest, but these are frequent sites of skin dryness in the elderly.

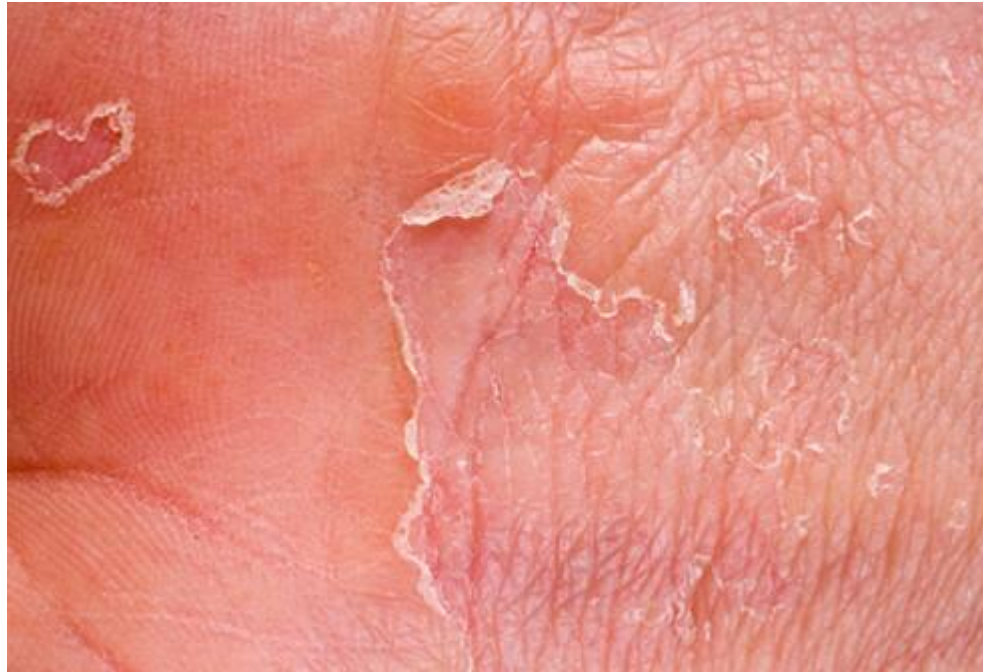


Common Dermatological Disease Conditions

- Most dermatologic diseases affect the body, but a complete discussion of this topic is beyond our scope.
- The most common skin disease of the body seen by the dermatologist is dry skin, known as eczema. The reason for this is overbathing.
- Use of excessive amount of cleanser and water contact eventually removes not only the sebum, but also the intercellular lipids, causing dry skin. The skin cracks, exposing tender dermal nerve endings, and itching ensues followed by scratching.
- This further damages the skin barrier and more itching and more scratching occur. Finally, the skin barrier is in complete disarray and the dermatologic disease of eczema is present.
- This sequence of events is known as the itch-scratch cycle.

Common Dermatological Disease Conditions

- Successfully controlling the eczema depends on stopping the itching, repairing the barrier, and restoring the skin to health.



Hygiene Needs

- This means body hygiene is a careful balance between removing enough bacteria to prevent disease and body odor while leaving the skin barrier undamaged.
- This is indeed quite a challenge. It would be nice to somehow develop a cleanser that could distinguish between sebum and intercellular lipids, removing the former while leaving the latter untouched.
- This should be the goal of all therapeutic body cleansers.

Skin Care Needs

- **The desire to bathe frequently has created moisturization as the major skin need of the body. Body moisturizers should create an optimal environment for healing and quell itch, leaving the skin smooth and soft.**
- **The moisturizer must function in hairy body areas and leave behind a breathable film that does not prevent sweat from evaporating from the body surface.**

Underarms



- The underarms have been removed from the general body discussion as they represent a unique body area medically known as an intertriginous site.
- Intertriginous sites are body areas where two skin surfaces meet. They include the armpit, beneath the female breasts, and between the upper inner thighs. In persons who are obese, other intertriginous sites may be present beneath the chin, beneath the abdomen, behind the knees, etc.
- Intertriginous sites are characterized by moisture retention, skin movement, and warmth. This environment, as mentioned previously, is perfect for the growth of fungus, yeast, and bacteria.
- The intertriginous sites are frequent sites of dermatologic disease.

Anatomy and Physiology

- The armpit is a particularly interesting intertriginous site because it combines the aforementioned factors with hair and abundant sweat glands. The armpit contains two types of sweat glands, eccrine and apocrine. Apocrine sweat glands do not participate in thermoregulation, but rather produce a yellowish scented sweat.
- Locations of apocrine sweat glands include the groin, buttocks, and scalp. Areola of the breast.
- Apocrine sweat provides a perfect growth media for odor producing bacteria. Further growth of these bacteria, in combination with fungus and yeast, can result in infections seen in the armpit.

Common Dermatological Disease Conditions

- Infection is clearly the most common dermatologic condition seen in the armpits. Infection may be due to fungus, yeast, or bacteria.
- The most common condition seen in the armpit is known as intertrigo. This is the growth of yeast and possibly fungus in the warm moist environment of the armpit that has had the skin barrier damaged by overhydration with eccrine sweat. Intertrigo presents as red, inflamed skin that may itch or burn.
- It is typically treated with a combination of topical antiyeast/antifungals and topical corticosteroid creams. Elimination of the sweat can prevent recurrence through the use of antiperspirants,

Common Dermatological Disease Conditions

- Bacterial infections of the armpit are usually due to staph or strep organisms. These are the most common pathogens found in the environment and on the body. The apocrine sweat in the armpit provides an excellent bacterial growth media.
- If the bacterial infection involves the skin of the armpit, it is known as impetigo. If the bacterial infection involves the skin around the exit of the hair from the skin, it is known as folliculitis.
- Open wounds that may be scabbed or oozing pus characterize both conditions. They are treated with oral and/or topical antibiotics.
- Again, elimination of the sweat is key to prevention.

Hygiene Needs

- It comes as no surprise that the key hygiene need in the armpit is the elimination of eccrine and apocrine sweat. Sweating is normal part of human physiology, but excessive sweating may occur in the armpits, just like on the hands and feet, and is characterized as hyperhidrosis.
- Controlling the sweat prevents body odor, skin barrier damage, infection, and emotionally disturbing wetness. This is the realm of antiperspirants, but oral medications and chemo denervation through botulinum toxin A are also used.

Skin Care Needs

- The skin care needs of the armpit are mainly irritation reduction from the aluminum salts used in antiperspirants and hair removal. Unfortunately, most topical antiperspirants cause irritation in the sensitive skin of the armpit.
- This can result in irritant contact dermatitis, especially if the skin barrier has already been damaged from overhydration. **Thus, the best way to maintain the health of the armpit is to use an effective, nonirritating antiperspirant.**
- The armpit skin barrier may be further irritated from hair removal techniques, especially in the female. The armpit is a challenging area to shave with a razor due to its concave nature. Using a well-designed razor and shaving cream to both soften and reduce friction are key in the armpit.
- Depilatories are typically too irritating for armpit hair removal.
- However, hair removal is an important method to control armpit odor, since the hair provides a large surface area for bacterial growth. Removal of the hair limits the amount of bacteria that can be present in the armpit.

The Female and Male Genitalia

- These areas have been separated for individual discussion because they represent unique skin interfaces with important hygiene and skin care needs.
- The male genitalia also form an interface between various skin types with and without hair. The lack of a large mucosal surface makes infection less of a problem, but the presence of hair is a complicating factor.

Female Anatomy and Physiology

- The female genitalia forms several skin interfaces. The hair bearing skin of the mons pubis joins the nonhair bearing skin of the labia and the mucosal surface of the labia abuts the urethra and vagina.
- A further skin interface is created where the keratinized skin of the inner thigh joins the transitional skin of the anus. Each of these sites form a location where skin disease can occur.
- The female genitalia is one of the intertrigenous zones previously discussed and as such is a warm, moist, dark place prone to infection from fungus, yeast, bacteria, and viruses. It is easily irritated and fragile with worsening fragility arising from the mucosal thinning that occurs with menopause.

Common Dermatologic Disease Conditions

- The most common dermatologic conditions involving the genitalia would then be
- infection and irritation. Infection is frequent, since the mucosa presents little barrier to
- infection. Common infections of the genitalia include herpes simplex, genital warts, yeast
- (usually *Candida albicans*), and fungus.
- Fungal infections of the groin, medically known as tinea cruris, occur from the same organism that causes fungal foot and toenail infections.
- Irritation in the groin usually arises from tight fitting clothing that does not control moisture. Just like other skin areas, overhydrated skin is easily damaged. Since this is an area of abundant apocrine and eccrine sweat glands accompanied by the wetness of vaginal secretions and urine, hygiene assumes great importance.

Hygiene Needs

- Hygiene of the female genitalia is an important, but overlooked, area. Most cleansers that are designed for keratinized body skin do not function well as cleansers for the mucous membranes of the female genitalia.
- They damage the mucosa causing itching, stinging, and pain. Yet, there is a need for cleansing to prevent infection and control odor.

Skin Care Needs

- The basic skin care need of the female genitalia is the management of wetness without the removal of the natural vaginal lubricants necessary to keep the tissues soft and supple.
- This is quite a challenge, which has not yet been met. It is desirable to absorb and remove the sweat, but the mucous secretions must remain in place to lubricate the tissues.

Anatomy and Physiology

- The male genitalia is characterized by the thin skin of the scrotum interfacing with the keratinized skin of the penis abutting the transitional mucosal skin of the head of the penis.
- In uncircumcised males, the head of the penis and the part of the penis beneath the foreskin is true mucosa.
- This true mucosa is a common site of infection, but is not found in the circumcised male.

Common Dermatological Disease Conditions

- The most common dermatologic disease seen in the male is known as “jock itch.” It represents a fungal infection, medically known as tinea cruris, again due to the same organisms that cause ringworm and toenail infections.
- The fungus can be passed between partners with direct contact, which is usually how females acquire the infection. Yeast infections of the penis can also occur, but this is less common in the circumcised male.
- Other infections, such as venereal disease may occur.

Hygiene Needs

- The hygiene needs of the male genitalia mainly focus around moisture and body odor control. Both are related because moisture is necessary for the growth of bacteria that cause body odor, thus eliminating wetness solves both problems.
- No personal antiperspirants exist for the area and moisture-absorbing powders usually become sticky, creating another problem.

Skin Care Needs

- The need for skin lubrication does not exist for the male like it does for the female. All of the body surfaces that move with locomotion are keratinized and do not require lubrication.

Reference

Draelos, Z.D. & Thaman, L.A. (ed.). 2006. Cosmetic formulation of skin care products, Volume 30.