

Surgical Emergencies

Dione P. Sacdalan, M.D., FPCS

University of the Philippines - Philippine General Hospital
Department of Surgery
Division of Colorectal Surgery



Case #1

- 25/F
- 2 day epigastric pain radiating to the RLQ
- (+) fever
- (+) vomiting
- (+) flank pain
- RLQ direct tenderness
- no rebound tenderness
- No CVA tenderness

What is lacking???

HISTORY

- LMP? – 2weeks ago
- Inguinal pain? - none
- Persistent pain? - yes
- Anorexia? - yes
- Fever timing?- after the pain

PE

- Rovsings?
- Psoas?
- Cough sign?
- Obturator?

Differential Diagnosis

- PUD
- UTI
- Urolithiasis
- Intestinal Colic
- Ovarian cyst
- Acute appendicitis

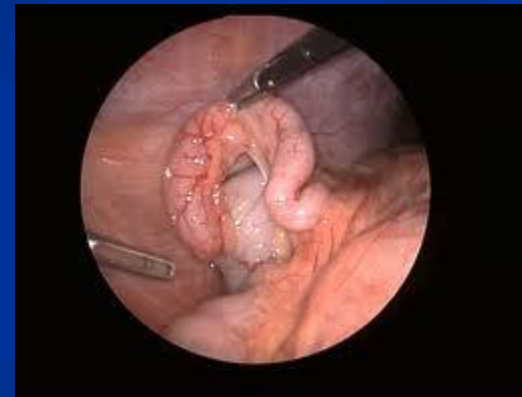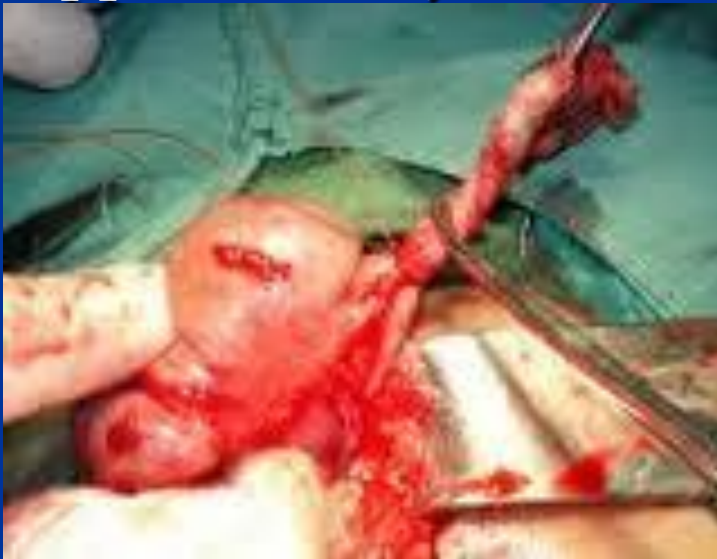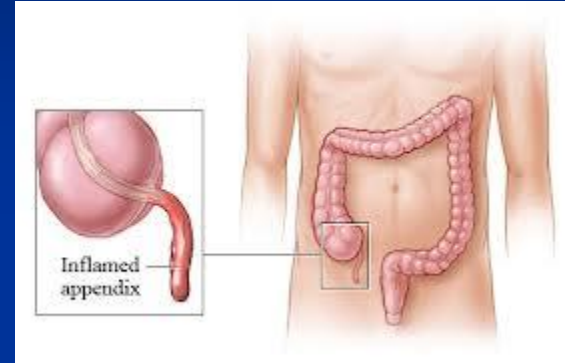
What would you order?

- CBC – WBC 13
- Urinalysis – pus cells 10-12
- Pregnancy test – negative
- Ultrasound - negative
- CT scan
- Diagnostic laparoscopy

ACUTE APPENDICITIS

Management

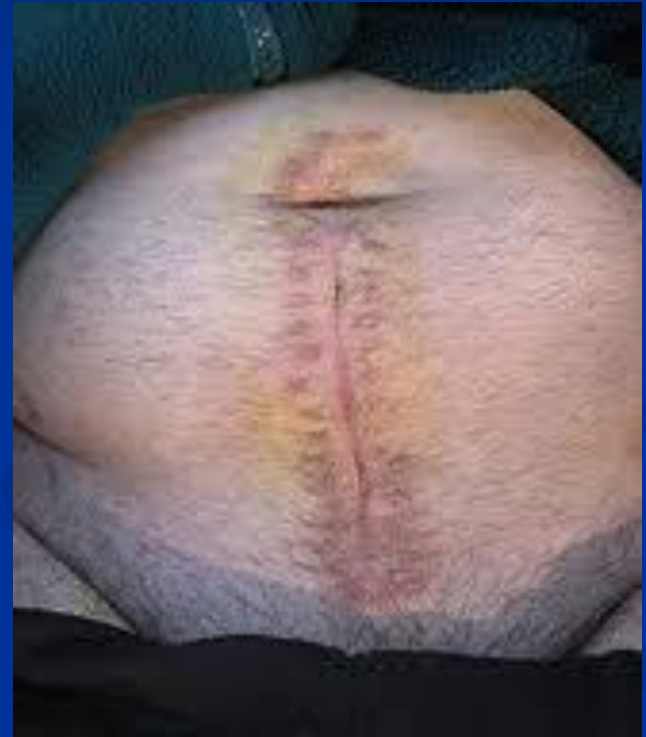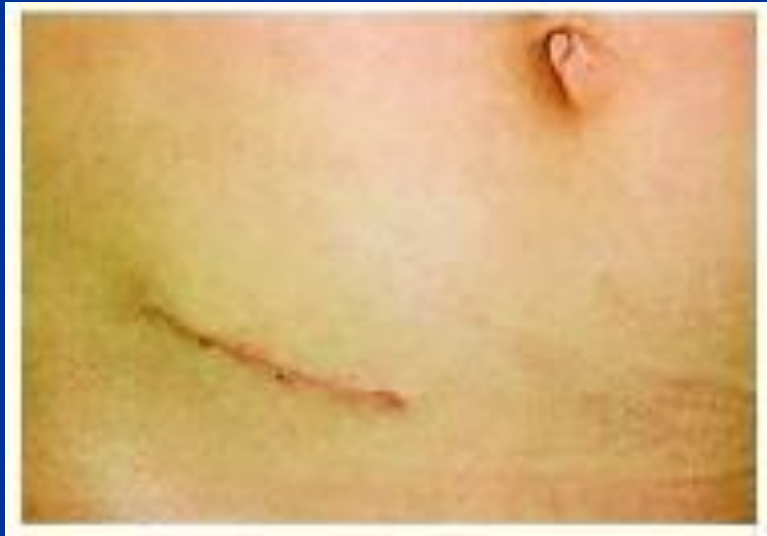- Serial abdominal examination
- Preoperative antibiotics
- Hydration
- appendectomy



Case #2

- Case #1 patient
- 6 hr delay in surgery
- Generalized abdominal pain and fever
- tachypnea
- Generalized tenderness
- Rebound and direct tenderness
- febrile

ACUTE APPENDICITIS → RUPTURED APPENDICITIS



Case #3

- 64/M
- 6 year – reducible R inguinoscrotal mass
- Painful inguinal bulge
- 5cm R inguinoscrotal bulge
- Slightly tender scrotum
- No fever

What is lacking???

HISTORY

- Occupation?
- Duration of irreducible mass?
- Bowel symptoms?

PE

- Abdominal examination?
- Transillumination?

Differential Diagnosis

- Orchitis
- Testicular torsion
- Scrotal abscess
- Testicular cancer
- Urolithiasis
- Incarcerated inguinal hernia

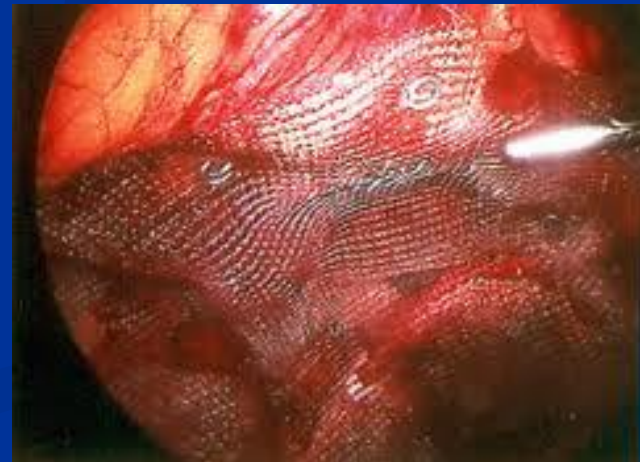
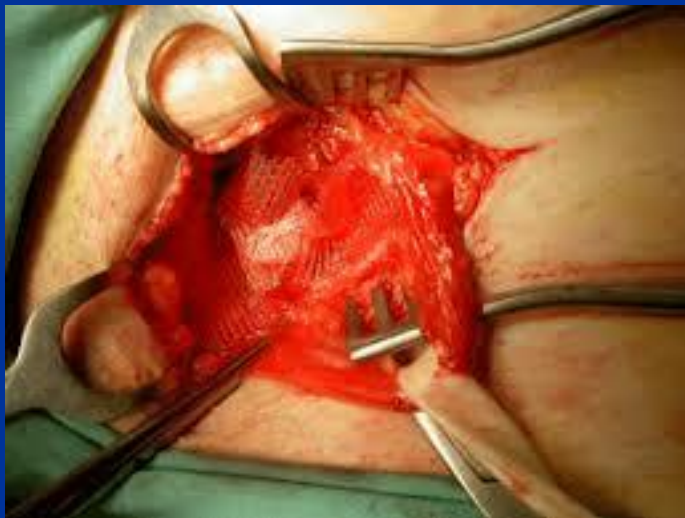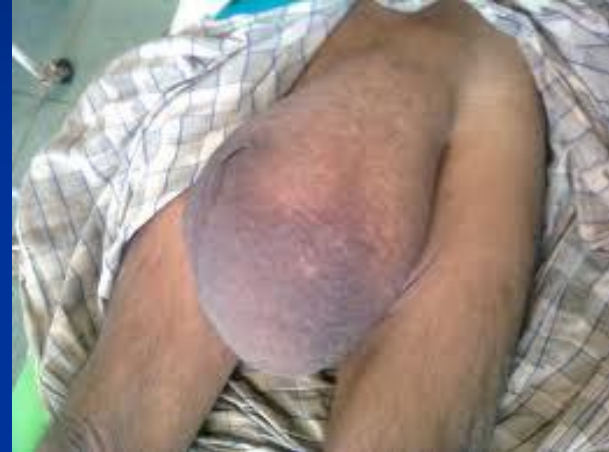What would you order?

- CBC – WBC 14
- Urinalysis – wbc 2-3, rbc 2-3
- Scrotal ultrasound

INCARCERATED INGUINAL HERNIA

Management

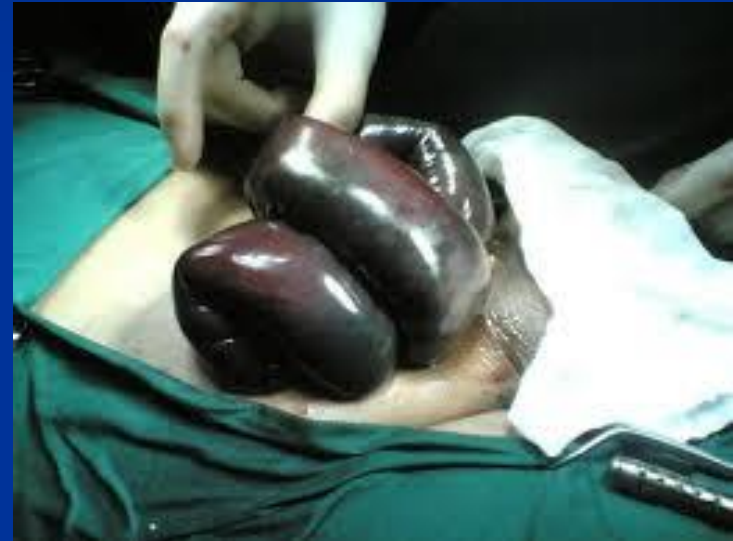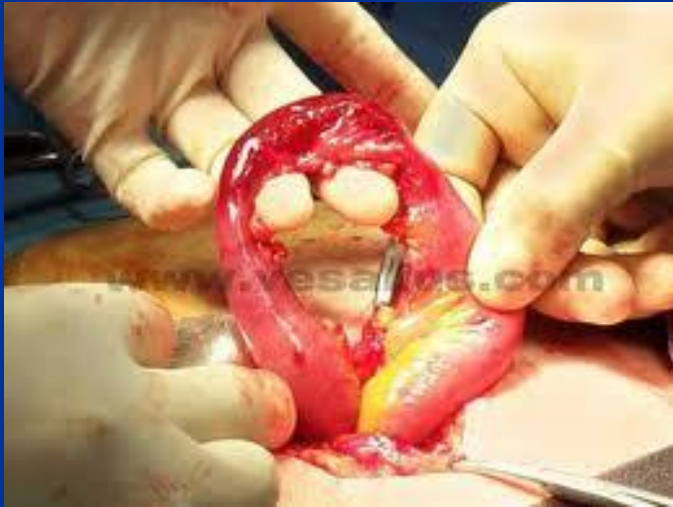- Hydration
- Antibiotics
- Inguinal exploration, reduction of bowels, mesh herniorrhaphy



Case #4

- Case #3 patient
- 12 hr delay in surgery
- Generalized abdominal pain
- Generalized abdominal tenderness
- febrile

INCARCERATED HERNIA → STRANGULATED HERNIA



Case #5

- 58/M, hypertensive
- 2 yr history of epigastric pain
- 1 hr generalised abdominal pain
- (-) fever
- Generalized tenderness
- (+) hypotension
- tachycardia

What is lacking???

HISTORY

- Timing and duration of abdominal pain?
- Vomiting??
Hematemesis??
- Dietary habits?
- Vices??
- Weight loss
- Cardiovascular history

PE

- Murphy's??
- DRE?

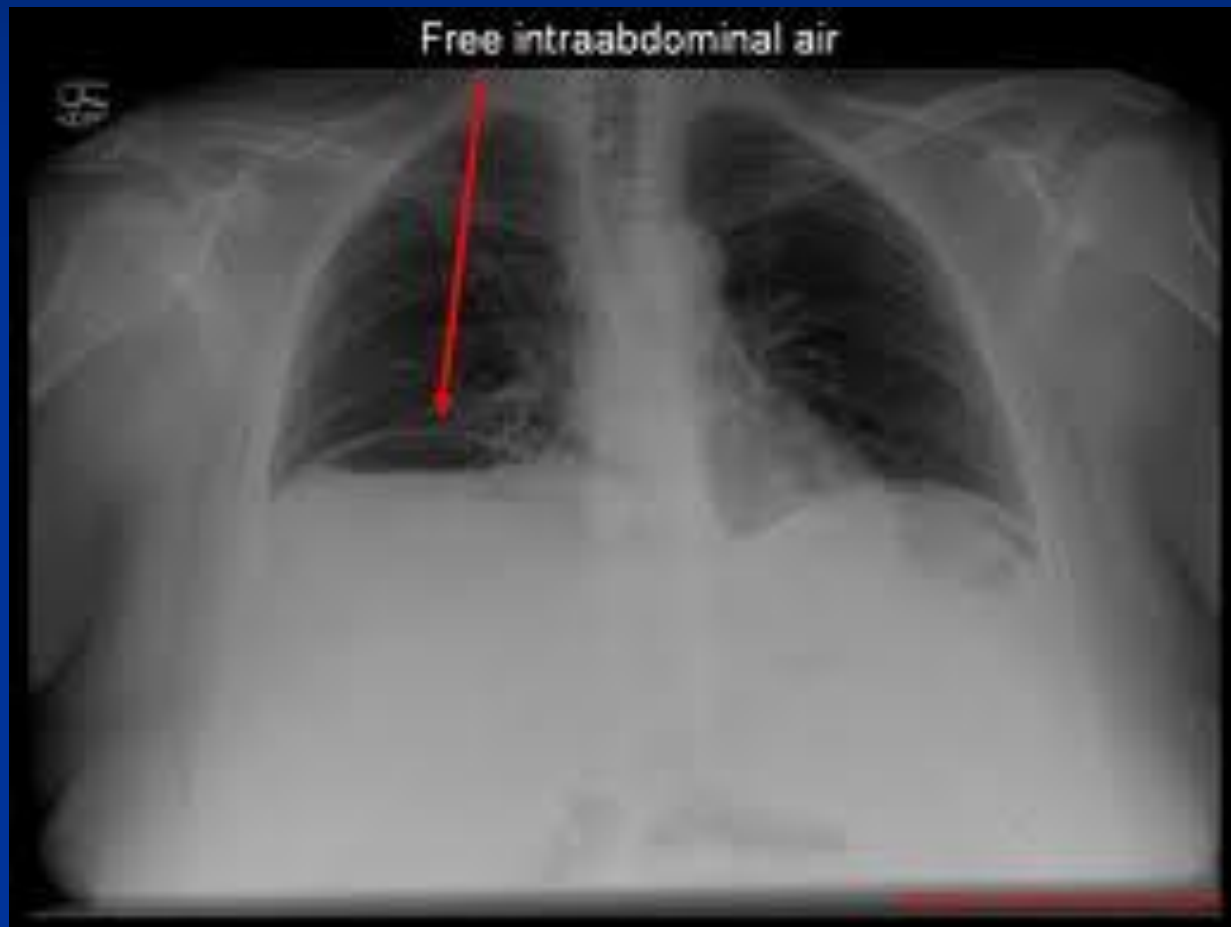Differential Diagnosis

- Calculous cholecystitis
- Pancreatitis
- Gastric cancer
- Mesenteric ischemia
- Intestinal perforation
- Myocardial Infarction

What would you order?

- Amylase/lipase
- CBC
- Ultrasound
- CT scan
- 12L ECG, cardiac enzymes
- Chest X-ray

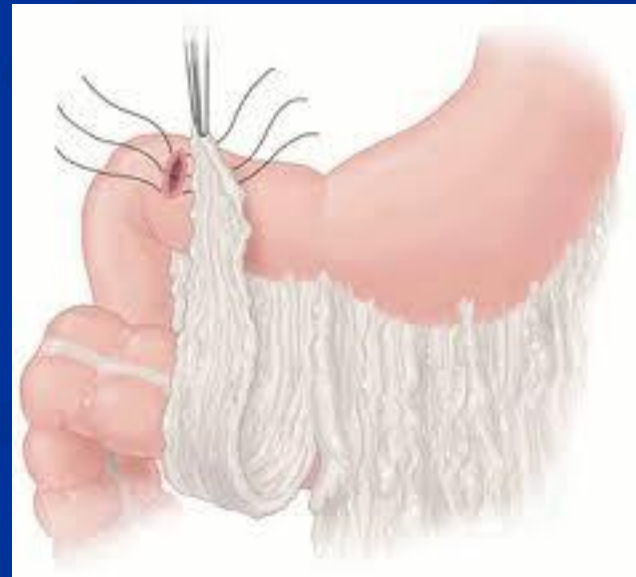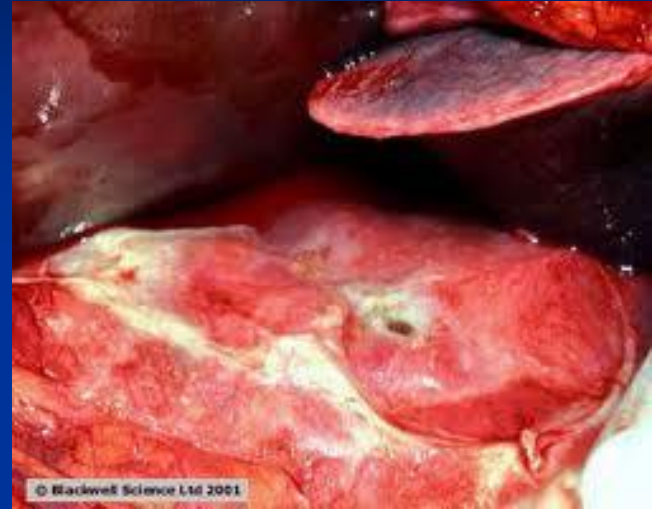Chest X-ray



PERFORATED PEPTIC ULCER

Management

- Hydration
- Antibiotics
- EL, omental patching



Case #6

- 56/M
- 2 month history of decreasing caliber of stools
- Sudden abdominal distention
- (+) vomiting
- No BM/flatus x 2 days
- Distended sl tender abdomen, all quadrants
- Hyperactive BS
- Collapsed rectal vault
- (-) fever

What is lacking???

HISTORY

- Weight loss?
- LGIB/UGIB??
- Previous surgeries?

PE

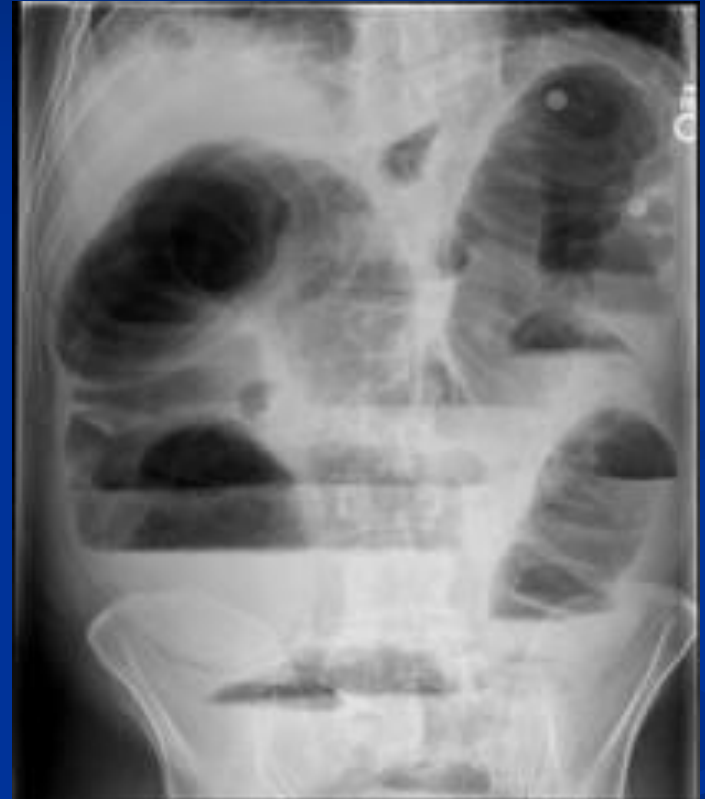- Fluid wave?
- Abdominal masses?

Differential Diagnosis

- Pancreatitis
- Ascites 2???
- Ruptured appendicitis
- Intestinal perforation
- Intestinal cancer
- Intestinal obstruction

What would you order?

- Plain abdomen upright and supine
- Colonoscopy
- Abdominal CT Scan
- CBC
- Ultrasound
- Chest X-ray PA



COMPLETE GUT OBSTRUCTION

Management

- Colonoscopy
- Medical decompression
- Antibiotics
- Exploratory laparotomy

UPPER GI/LOWER GI BLEEDING

Differential Diagnosis for UGIB/LGIB

UGIB

- Esophageal varices
- Gastric/duodenal ulcers
- Gastric CA
- Dieulafoy's lesion
- Mallory Weiss tears

LGIB

- Hemorrhoids
- Polyps
- Colorectal CA
- Angiodysplasia
- Diverticulosis
- Massive UGIB

Management of UGIB/LGIB

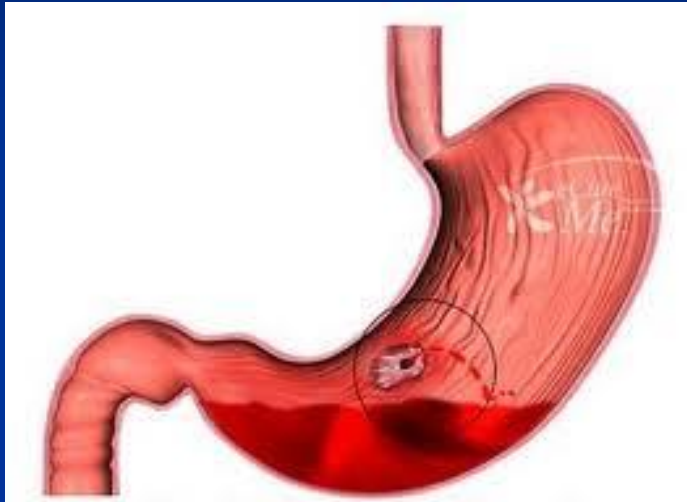
UGIB

- Fluid resuscitation
- Localization of bleeding site
- EGD
- Endoscopic control of bleeding
- EL, ligation of bleeders/gastrectomy

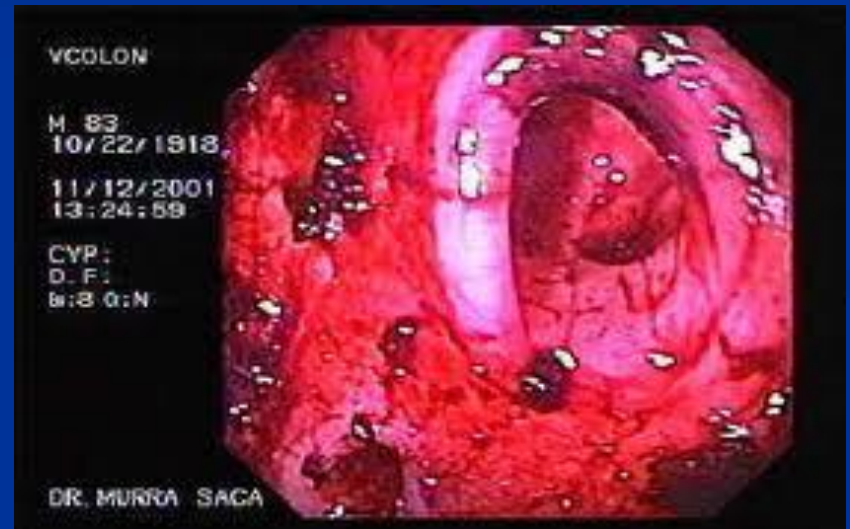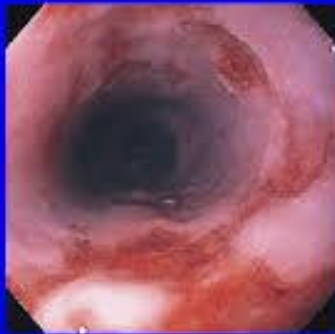LGIB

- Fluid Resuscitation
- Localization of bleeding site
- Colonoscopy
- Endoscopic control of bleeding
- EL, total colectomy

Endoscopy



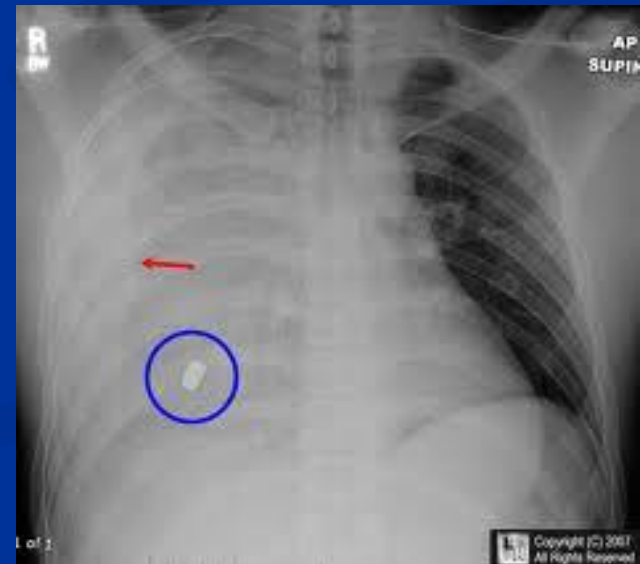
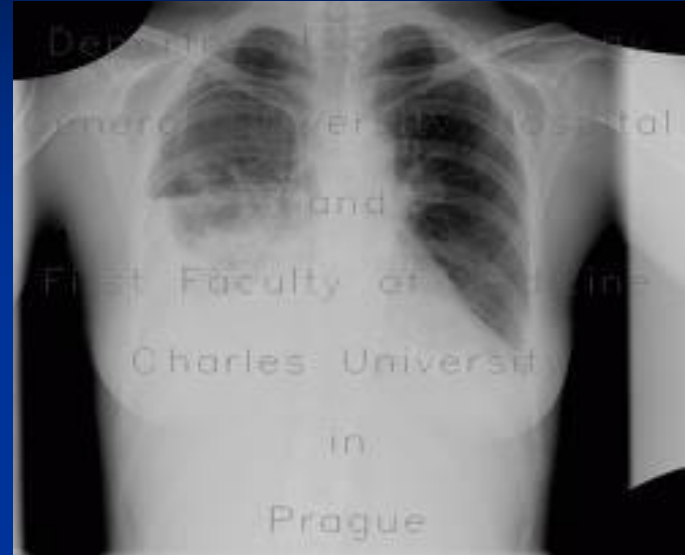UGI Bleeding



THORACOABDOMINAL PERFORATING INJURIES

Penetrating Thoracic Injuries

- Chest P.E
- Duration of Injury
- Hemodynamic Instability
- Mechanism of Injury

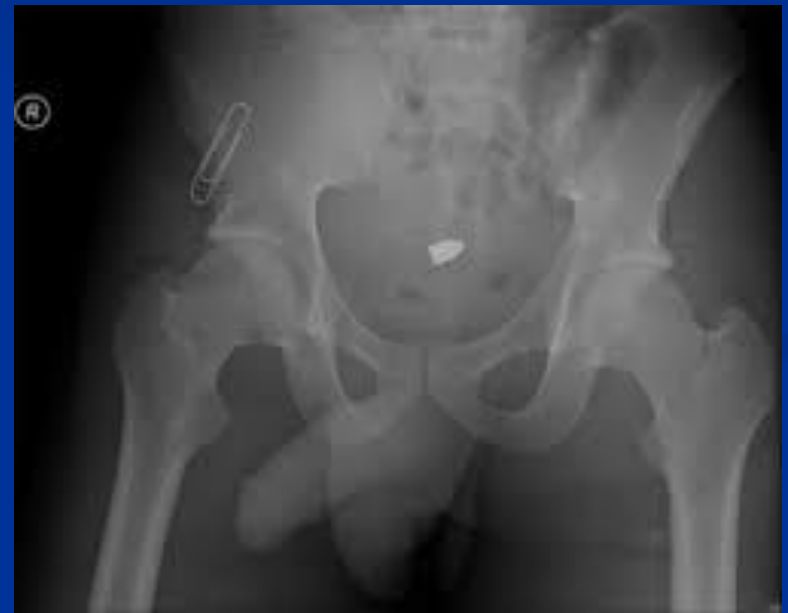

Management

- ABC's
- Chest X-ray
- Subxiphoid Ultrasound
- CTT insertion
- Thoracotomy
- Thoracentesis/pericardiectomy

Penetrating Abdominal Injuries

- Abdominal P.E
- Duration of Injury
- Hemodynamic Instability
- Mechanism of Injury



Management

- ABC's
- Chest X-ray PA upright
- Abdominal X-rays
- FAST
- CT-Scan
- DPL
- Exploratory Surgery

Thank You!